

# Mast Cells Kinetics during Experimental *Schistosomiasis mansoni* in Mice

Parviz Kermanizadeh<sup>\*1</sup>, Paul Hagan<sup>2</sup> and David Crompton<sup>3</sup>

<sup>1</sup>Division of Immunology, Faculty of Medicine, University of Medical Sciences of Tabriz, Tabriz, Iran; <sup>2</sup>Division of Infection and Immunity, Joseph Black Building, IBLs, University of Glasgow, Glasgow G12 8QQ; <sup>3</sup>Division of Environmental and Evolutionary Biology, the Graham Kerr Building, IBLs, University of Glasgow, Glasgow G12 8QQ, U.K.

## ABSTRACT

Increased number of mast cells at the site of infection is widely regarded as important host defense against parasites. The kinetics of mucosal mast cells and connective tissue mast cells responses were studied in the intestines of 68 female CFLP mice infected with 100 *Schistosoma mansoni* cercariae. The number of mucosal mast cells and the connective tissue mast cells increased from week 3 and week 6 respectively. While the number of connective tissue mast cells was still increasing during the chronic phase of the infection, the number of mucosal mast cells continuously decreased as the infection matured. The number of both cells was always greater in the proximal part of the small intestine. Their distribution within the injured areas appeared to depend on other factors than parasites. *Iran. Biomed. J. 5 (1): 11-14, 2001*

**Keywords:** Mast cell, Schistosomiasis, *Schistosoma mansoni*

## INTRODUCTION

The hallmark of the host responses to the parasitic helminth infections in the intestine is the increase of the mast cells numbers in the mucosa [1]. Detailed descriptions of this feature have come from studies of the nematode *Nippostrongylus brasiliensis* in rats in which the increase numbers of the mast cells was associated with the worm expulsion from the gut. Locally the accumulation of the mast cells in parasitized tissues can be used for immunity. Also, secondary challenge has confirmed that basophils [2] and mast cells [3] may be contributed to the prevention of reinfection in the gastrointestinal parasitism and the early stage of schistosomiasis [4]. The importance of the mast cells in parasitic infection has been investigated extensively [5, 6]. Mast cells are involved not only in the pathology of parasitic infections but also in other gastrointestinal inflammatory diseases such as: food induced hypersensitivity, ulcerative colitis, coeliac disease, *Helicobacter pylori* or ethanol-induced gastritis and ulcer [7]. The role of the mast cells during schistosome infection is less well-defined and remains a subject for debate. Recent evidence shows that the mast cells produce a variety of

multifunctional cytokines. The major role of IgE in *Schistosoma* infection has been demonstrated by the association of high levels of specific anti-schistosome IgE with resistance to reinfection with *S. haematobium* [8] and *S. mansoni* [9, 10]. The involvement of IgE in the mast cells stimulation may be important in *Schistosoma* infection. While most attention has been focused on studying the role of the mast cells on gastrointestinal dwelling parasites, very little attention has been applied to the blood resident *Schistosoma*. Therefore, in this study, we report the kinetics of the mast cells during the acute and chronic phases of the infection.

## MATERIALS AND METHODS

A total of 68 outbred female CFLP mice, between 30-37 g, were infected percutaneously with 100 cercariae of a laboratory maintained Puerto Rican strain of *Schistosoma mansoni*. Five infected mice were killed on weeks 1, 2, 3, 4, 5, 6, 7, 8, 11, 12, 14, 16 post infection and 3 or 4 uninfected control mice were killed on weeks 3, 4, 5, 7, 9, 11, 16 post infection. The small intestines were removed and all mesenteric tissues were trimmed away and treated using the modification of the Swiss role technique

\*Corresponding Author;

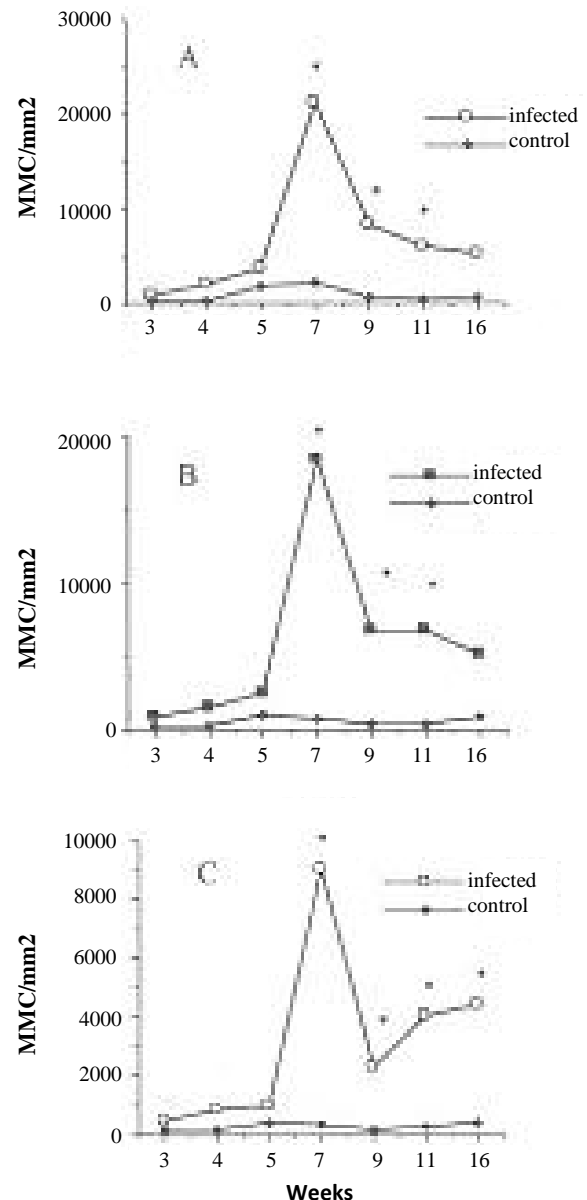
originally described by Domingo and Warren [11]. The intestinal tissues were returned to Carnoy's fixative for 24 h. The tissues were embedded in the paraffin wax (50°C) and sectioned at 5  $\mu\text{m}$  thickness before staining. Sections were stained with 1% astra blue for 30 min and counter staining with 0.5% safranin. One mouse was perfused to give an indication of the adult worm burden. The number of mast cells was counted at three parts of the intestine using the method previously described [12]. Two types of the mast cells have been identified in the intestinal tissue. Those found in the crypts and in the villi were considered as mucosal mast cells (MMC) whereas, those found in the submucosa and muscle layers were considered as connective tissue mast cells (CTMC).

## RESULTS

**Mucosal mast cells in the anterior, middle and posterior portion of the small intestine.** MMC numbers in the control mice were estimated at 130, 284, and 105 per  $\text{mm}^2$  on week 3. The MMC numbers increased in control mice and reached 644, 883, and 380 per  $\text{mm}^2$  in anterior, middle and posterior portion of the small intestine respectively by week 16. Such an increase may be due to the age of mice. At the start of the experiment, most of the MMC were found in the lamina propria of the infected mice, but by week 7 post infection, MMC were present throughout the whole width of the intestine from the lamina propria to the tips of the villi (21,144, 18,427 and 8,998 per  $\text{mm}^2$ ) when compared with the control mice. Thereafter, the number of MMC decreased steadily by week 16 post infection (Fig.1).

**Connective tissue mast cells in the anterior, middle and posterior portion of the small intestine.**

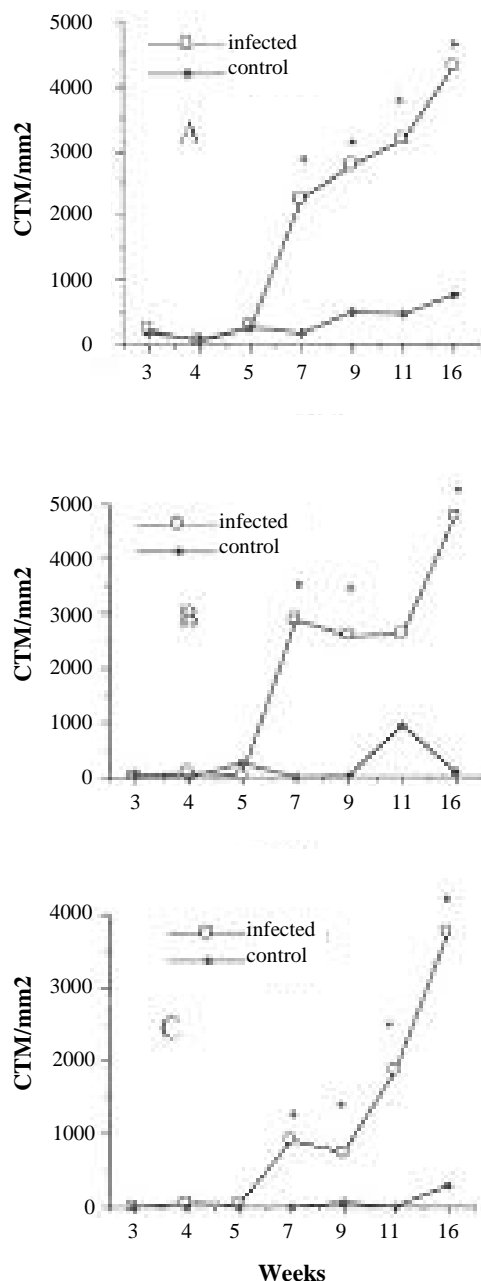
In both infected and control mice, CTMC were located in the submucosa and muscle layers. In control mice, their numbers increased from 158, 58, and 0 per  $\text{mm}^2$  at week 3 to 761, 105, and 281 per  $\text{mm}^2$  at week 16 respectively. In *S. mansoni*-infected mice, a large number of CTMC were observed at 6 weeks post infection, increasing from 336, 172, and 177 per  $\text{mm}^2$  to 2232, 2850 and 918 per  $\text{mm}^2$  at weeks 7 respectively and the number of the cells were increased to 4280, 4744 and 3746 per  $\text{mm}^2$  respectively until the end of the experiment (Fig. 2).



**Fig. 1.** Mean number of MMC at the (a) anterior (b) middle (c) posterior portion of the infected and control small intestine. [\*Mann-Whitney test shows that difference between the infected ( $n = 5$ ) and controls ( $n = 3-4$ ) are significant  $P < 0.05$ ].

## DISCUSSION

Mast cells besides their participation in inflammatory responses, produce tumor necrosis factor [13] and other cytokines [14] that are potentially important in the regulation of the inflammatory processes and other immune reactivities. For these functions, the degranulation



**Fig. 2.** Mean number of CTMC at the (a) anterior (b) middle (c) posterior portion of the infected and control small intestine. [\*Mann-Whitney test shows that difference between the infected ( $n = 5$ ) and controls ( $n = 3-4$ ) are significant  $P < 0.05$ ].

events that occur through cross-linking of the specific IgE on the surfaces are crucial. Degranulation can lead to immediate hypersensitivity and acute inflammation. Despite the central role of the mast cells in helminth infections, the effect of schistosomes on intestinal tissue received less attention. The study of the mast cells and IgE levels during infection could help to elucidate the biology of the parasite. In this study, the induction of mucosal and connective tissue mast

cells by *S. mansoni* infection has been examined in CFLP mice. For the detection of MMC and CTMC, Carnoy's fixative generally is used. Astra blue has a high affinity for mucopolysaccharides present in the mast cell's granules. Since the nature of the proteoglycans in mast cell granules are different, by using a non-metachromatic astra blue and safranin dye, MMC and CTMC can be differentiated. Recently, astra blue was shown to be a general stain for mast cell granules. In addition to the gut dwelling mast cells, skin resident mast cells also were observable using this dye. All the mast cells found in the submucosa and muscle layer are considered to be connective tissue mast cells and those in the epithelium, lamina propria, and mucosal glands consider to be mucosal mast cells. MMC were increased slowly during week 1-2 post infection and first observed at the bottom of the villi in the lamina propria and only later in the epithelium and at the tops of the villi. MMC increased about week 3 post-infection and reached their maximum numbers at week 7 post infection and then decreased and remained at a steady number between week 11 to 16 post infection. The number of MMC was higher in the anterior than the posterior of the small intestine. CTMC also started to increase at week 6 post infection and remained at the high level until the end of the experiment. The earlier increase of the MMC at week 3 post infection seemed to be schistosomula dependent, rather than the adult worm, but the increase of the CTMC coincided with development of adult worms and egg production. As the infection matured, the number of MMC reduced and the CTMC remained at a high level during the chronic phase of *S. mansoni* infection. Although it is impossible to know exactly what the relationships between the mast cells and parasites really are, the temporal relationships of parasite maturation and egg deposition do allow room for some speculation. MMC proliferation in the intestine of parasitized animals is a localized response and depends on the presence and the level of the offending helminth [15]. *S. mansoni* is present in the mesenteric veins of lower bowel and access of parasite eggs to the large intestine and the posterior small intestine are greater than middle and anterior small intestine. This situation did not reflect the number of mast cells, which were higher in the anterior small intestine than in posterior small intestine. The results from these experiments illustrate some points: (1) MMC increased earlier, at about week 3 and CTMC at week 6 post infection; (2) The distribution of MMC and CTMC were not equal over the intestine, always greater number of

mast cells were found at the anterior part of the intestine than the posterior; (3) The number of MMC reached a peak and then reduced through the duration of the infection. On the other hand, the number of CTMC remained stable as the infection matured. On the basis of the above observations, it is possible to speculate that: I) Mast cells may be involved in the immune responses to *S. mansoni* through local inflammatory responses, probably through the leukocyte recruitment. The mast cells may reduce the chance of worms and eggs survival by altering the tissue environment, diverting the young worms pathway to unsuitable sites within the host body during tissue migration and delaying or preventing their development. Non-hospitable tissues have been described to play a crucial role in parasite reinfection [16]. II) The existence of mast cells hyperplasia during early and at the chronic phase of the infection was depended on continuous doses of *S. mansoni* antigen and is consistent with concomitant immunity described by Smithers [17]. Since the inflammatory processes needed to be active may require continuous stimulation. III) Mast cells may proliferate in response to *S. mansoni* stimulation but their distribution and accumulation within the body and in the injured areas may be determined by other factors.

## REFERENCES

1. Miller, H.R.P. (1987) Immunopathology of nematode infection and expulsion. In: *Immunopathology of the Small Intestine* (Marsh, M.N. eds.), John Wiley press, New York. pp. 177-208.
2. Rothwell, T.L.W. and Dineen, J.K. (1972) Cellular reaction in guinea-pigs following primary and challenge infection with *Trichostrongylus colubriformis* with special reference to the roles played by eosinophils and basophils in rejection of the parasite. *J. Immunol.* 22: 733-745.
3. Rothwell, T.L.W. (1989) Immune expulsion of parasitic nematodes from the alimentary tract. *Aust. J. Parasitol.* 19: 139-167.
4. Li Hsu, S.Y., Hsu, H.F., Penick, G.D., Schiller, H.J. and Cheng, H.F. (1979) Immunoglobulin E, mast cells, and eosinophils in the skin of Rhesus monkeys immunized with X-irradiated cercariae of *Schistosoma mansoni*. *Int. Arch. Allergy Immunol.* 59: 383-393.
5. Charbon, J.L., Spahni, M., Wicki, P. and Pfister, K. (1991) Cellular reactions in the small intestine of rats after infection with *Fasciola hepatica*. *Parasitol. Res.* 77: 425-429.
6. Lee, T.D.G., Swieter, M. and Befus, A.D. (1986) Mast cell responses to helminth infection. *Parasitology Today* 2: 186-191.
7. Wershil, B.K. (1995) Role of mast cells and basophils in gastrointestinal inflammation. In: *Human Basophils and Mast cells*. (Marone, G. eds.), Karger, Basel, Switzerland. pp. 187-203.
8. Hagan, P., Blumenthal, U.J., Dunn, D., Simpson, A.J.G. and Wilkins, H.A. (1991) Human IgE, IgG<sub>4</sub> and resistance to reinfection with *S. haematobium*. *Nature (London)*. 349: 243-245.
9. Rihet, P., Demeure, C., Bourgois, A., Prata, A. and Dessein, A.J. (1991) Evidence for an association between human resistance to *Schistosoma mansoni* and high anti-larval IgE level. *Eur. J. Immunol.* 21: 2679-2686.
10. Dunne, D.W., Butterworth, A.E., Fulford, A.J.C., Kariuki, H.C., Langley, J.G., Ouma, J.H., Capron, A., Pierce, R. and Sturrock, R.F. (1992) Immunity after treatment of human schistosomiasis: association between IgE antibodies to adult worm antigens and resistance to reinfection. *Eur. J. Immunol.* 22: 1483-1494.
11. Domingo, E.O. and Warren, K.S. (1969) Pathology and pathophysiology of the small intestine in murine *S. mansoni*, including a review of the literature. *Gastroenterol.* 56: 231-240.
12. Kermanizadeh, P., Crompton, D.W.T. and Hagan, P. (1997) A simple method for counting cells in tissue sections. *Parasitology Today* 13: 405.
13. Benyon, R.C., Bissonete, E.Y. and Befus, A.D. (1991) Tumor necrosis factor a dependent cytotoxicity of human skin mast cells is enhanced by anti-IgE antibody. *J. Immunol.* 147: 2253-2258.
14. Gordon, J.R. and Galli, S.J. (1991) Release of both preformed and newly synthesized tumor necrosis factor- (TNF- )/cachectin by mouse mast cells stimulated via the Fc RI. A mechanism for the sustained action of mast cell-derived TNF- during IgE-dependent biological response. *J. Exp. Med.* 174: 103-107.
15. Kho, W.G., Chai, J.Y., Chun, C.H. and Lee, S.H. (1990) Mucosal mast cell responses to experimental *Fibricola seoulensis* infection in rats. *Seoul. J. Med.* 31: 191-199.
16. Gerken, S.E., Mota-Santos, T.A. and Vaz, N.M. (1990) Evidence for the participation of mast cells in the innate resistance of mice to *Schistosoma mansoni*: Effects on *in vivo* treatment with the ionophore. *Braz. J. Med. Biol. Res.* 23: 559-565.
17. Smithers, S.R. and Terry, R.J. (1969) Immunity in schistosomiasis. *Ann. NY. Acad. Sci.* 160: 826-840.