

Identification of a Novel Splice Site Mutation in *RUNX2* Gene in a Family with Rare Autosomal Dominant Cleidocranial Dysplasia

Ebrahim Jamali¹, Raziye Khalesi², Fatemeh Bitarafan³,
Navid Almadani^{*4} and Masoud Garshasbi^{2*}

¹Department of Genetics, School of Basic Science, Tonekabon Branch, Islamic Azad University, Tonekabon, Iran; ²Department of Medical Genetics, Faculty of Medical Sciences, Tarbiat Modares University, Tehran, Iran; ³Department of Cellular and Molecular Biology, North Tehran Branch, Islamic Azad University, Tehran, Iran; ⁴Department of Genetics, Reproductive Biomedicine Research Center, Royan Institute for Reproductive Biomedicine, ACECR, Tehran, Iran

Received 17 January 2020; accepted 11 March 2020; published online 19 October 2020

ABSTRACT

Background: Pathogenic variants of *RUNX2*, a gene that encodes an osteoblast-specific transcription factor, have been shown as the cause of CCD, which is a rare hereditary skeletal and dental disorder with dominant mode of inheritance and a broad range of clinical variability. Due to the relative lack of clinical complications resulting in CCD, the medical diagnosis of this disorder is challenging, which leaves it underdiagnosed. **Methods:** In this study, nine healthy and affected members of an Iranian family were investigated. PCR and sequencing of all exons and exon-intron boundaries of *RUNX2* (NM_001024630) gene was performed on proband. Co-segregation analysis was conducted in the other family members for the identified variant. Additionally, a cohort of 100 Iranian ethnicity-matched healthy controls was screened by ARMS-PCR method. **Results:** The novel splice site variant (c.860-2A>G), which was identified in the intron 6 of *RUNX2* gene, co-segregated with the disease in the family, and it was absent in healthy controls. Pathogenicity of this variant was determined by several software, including HSF, which predicts the formation or disruption of splice donor sites, splice acceptor sites, exonic splicing silencer sites, and exonic splicing enhancer sites. *In silico* analysis predicted this novel variant to be disease causing. **Conclusion:** The identified variant is predicted to have an effect on splicing, which leads to exon skipping and producing a truncated protein via introducing a premature stop codon. **DOI: 10.52547/ibj.25.4.297**

Keywords: Cleidocranial dysplasia, *RUNX2*, Splice site

Corresponding Author: Masoud Garshasbi

Department of Medical Genetics, Faculty of Medical Sciences, Tarbiat Modares University, Tehran, Iran; Tel.: (+98-21) 82884569;

E-mail: masoud.garshasbi@modares.ac.ir

****Co-corresponding author:** Navid Almadani

Department of Genetics, Reproductive Biomedicine Research Center, Royan Institute for Reproductive Biomedicine, ACECR, Tehran, Iran;

Tel.: (+98-21) 23562119; E-mail: Navidalmadani@yahoo.com

INTRODUCTION

Cleidocranial dysplasia/Dysostosis (CCD; MIM# 119600) or Marie and Sinton syndrome is a rare hereditary disease with autosomal dominant inheritance, clinically presented with congenital skeletal malformations of bones such as clavicular hypoplasia/aplasia, abnormal sutures and fontanelles, short stature, Wormian bones, and

supernumerary teeth^[1].

The first case of CCD was described by Martin with lack of clavicle^[2]. In 1967, Keats^[3] reported additional manifestations for this disease, including abnormalities of long bones, the base of the skull, and the spine. Later, Jarvis and Keats^[4] comprehensively reviewed skeletal anomalies in CCD.

CCD with an estimated prevalence rate of 1:1000,000 has been indicated to have complete

List of Abbreviations:

ARMS, Amplification Refractory Mutation System (ARMS); **CCD**, Cleidocranial dysplasia; **HSF**, human splicing finder; **RUNX2**, runt-related transcription factor 2; **VEP**, variant effect predictor

penetrance^[5,6]. Due to the relatively less medical complications in comparison with other skeletal dysplasia, CCD is most likely underdiagnosed. It may be seen at any age, and both sexes are affected approximately equally^[7].

The mutations in *RUNX2* gene, located at chromosome 6p21, cause this disorder^[5,8]. *RUNX2* is a key transcription factor necessary for osteoblast differentiation. It binds to a DNA sequence element called RUNX-binding site (PyGPyGGT) and regulates number of bone-related genes^[9]. Any mutation in *RUNX2* will cause defects in the membranous and endochondral bone formation^[5,6].

So far, few cases with CCD have been reported from Iran. Therefore, the mutation spectrum of Iranian CCD

patients is still poorly understood. Herein, we report a novel mutation in *RUNX2* gene in an Iranian family with several affected members.

MATERIALS AND METHODS

Patient

We studied nine healthy and affected members of a family in three generations (Fig. 1A). Affected individuals characterized by normal head circumference, mild frontal bossing, wide and prominent forehead, mild hypertelorism, broad and depressed nasal bridge, mild midface hypoplasia, crowded, irregular, and wide-spaced teeth, triangular

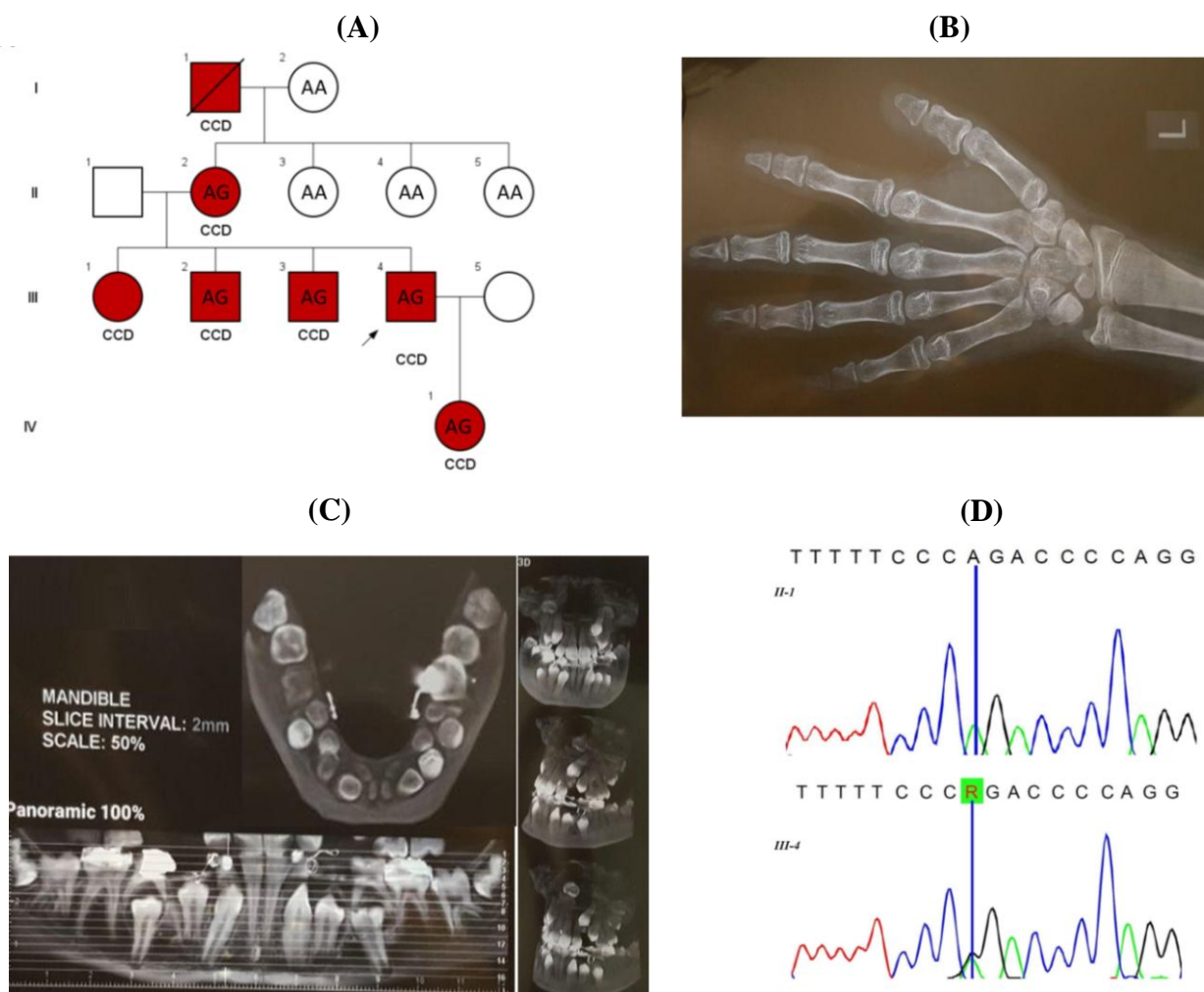


Fig. 1. (A) The pedigree of the family with CCD and genotype of the studied samples for the c.860-2A>G variant in *RUNX2*. (B) Left hand X-ray of IV1 showing shortened middle phalange, hypoplastic distal phalanges, brachydactyly (especially the fifth digit), and mildly longed second metacarpus. (C) Panoramic mandibular X-ray of IV1 demonstrating dental caries, crowded, irregular and wide spaced teeth, and supernumerary teeth, occult, and unruptured multiple permanent teeth. (D) Sequencing chromatograms for the region of the c.860-2A>G variant in the *RUNX2* gene in one healthy (II-1) and one affected member (III-4) of the family. “R” designates purine (A or G) ribonucleotides.

face, no orofacial clefting, narrowed shoulder, short ribs, hypoplastic clavicles, narrowed chest, dental caries, shortened middle phalanges, hypoplastic distal phalanges, brachydactyly, mild lumbar lordosis, mildly longed second metacarpus, mild osteopenia, normal bone age, hypoplastic iliac wings and broad iliac notch (bilateral), multiple wormian bones in skull X-ray, supernumerary teeth, occult, and unruptured multiple permanent teeth, and proportionate short stature. Available skeletal radiography, including left hand and panoramic mandibular X-ray of IV1, are shown in Figure 1B and 1C, respectively. Additionally, a group of 100 healthy individuals from Iranian population consisting of 55 males and 45 females were randomly collected. The frequency of the identified novel variant was checked in this healthy control group by ARMS-PCR method.

DNA extraction and primer design

Approximately 5 mL of peripheral blood was collected from the proband, four other affected members, and four healthy individuals of this family. Genomic DNA was extracted using DNA isolation kit (Roche Life Science). Primers were designed in order

to amplify all the coding regions and exon-intron boundaries of *RUNX2* gene (NM_001024630) using Primer3 software (Table 1).

PCR sequencing

Eight amplicons covering the exons and exon-intron boundaries of *RUNX2* were amplified using an initial denaturation step at 95 °C for 5 min, followed by 30 cycles with each at 95 °C for 40 s, annealing at the optimized temperatures, which are shown in Table 1, for 30 s, and 72 °C for 30 s, followed by final extension at 72 °C for 10 min. The PCR products were run on 2% agarose gel and were stained by ethidium bromide. All the PCR products were sequenced by an ABI 3730X1 sequencer machine. Sequencing results were analyzed by CodonCode Aligner software (v.7.0.1).

ARMS PCR

PCR amplifications were performed in two distinct tubes. The total volume of each reaction was 25 µL and contained Taq DNA polymerase 2× master mix red, 2 mm of MgCl₂ (Ampliqon, Denmark), primers at a final concentration of 0.2 pM, and 30 ng of genomic DNA.

Table 1. Amplification primer sequences, PCR product size, and optimized annealing temperatures

	Primer's ID	Sequences	PCR product (bp)	Optimized annealing temperatures (°C)
PCR-sequencing primers	E1-RUNX2-F	TGCTCATTCTCTTTTTGTTTTG	598	61
	E1-RUNX2-R	TTTCTTCTGGTGAGGGTTAATG		
	E2-RUNX2-F	CCTGATAAGACACATCATTTGC	309	62
	E2-RUNX2-R	TCATCAAAGGAGCCTAATGTG		
	E3-RUNX2-F	CAGATGCTTCATTCCTGTGC	359	62
	E3-RUNX2-R	CATCAAAGGAGCCTAATGTGC		
	E4-RUNX2-F	TGCTGCTGTGTAATCATCAAC	230	62
	E4-RUNX2-R	CCTCATAGGGTCTCTGGAAAC		
E5-RUNX2-F	TGGAAGGCATTATGTAGACAAG	397	62	
E5-RUNX2-R	ACATCTCCTCTGGTAGCCC			
E6-RUNX2-F	AAGGCTGCAATGGTTGCTATAC	299	60	
E6-RUNX2-R	GTGAGCATGGATGAGACAGG			
E7-RUNX2-F	TGCTTCTCCTTCTCTCTTGG	596	62	
E7-RUNX2-R	GCCCTTTTCTAATACCAGTGC			
E8-RUNX2-F	TGGCTTGCTGTTTCCTTTATG	653	64	
E8-RUNX2-R	TGATACGTGTGGGATGTGG			
ARMS-PCR primers	RUNX2-Fm	TACTAAAGATTTTTCTTTTTCTTTTTACAG	330	60
	RUNX2-Fn	TACTAAAGATTTTTCTTTTTCTTTTTACA		
	RUNX2-RC	ATTTGCCAGTTGTCATTCCC		
	Internal control-F	TGCTCATTCTCTTTTTGTTTTG	598	
Internal control-R	TTTCTTCTGGTGAGGGTTAATG			

The temperature protocol for PCR amplification was as follows: initial denaturation at 95°C for 5 min, followed by 30 amplification cycles of 30 s at 95°C, 30 s at 60°C and 30 s at 72°C, followed by final extension at 72°C for 10 min. The PCR products were run on 2% agarose gel and stained by ethidium bromide. Two samples with known genotypes were used as positive (heterozygote) and negative (homozygote for normal allele) controls.

***In silico* prediction of pathogenicity**

In this study, pathogenicity of the discovered variant was determined by several software such as Mutation taster (<http://www.mutationtaster.org/>), VEP (<http://www.ensembl.org/Tools/VEP>) and HSF (<http://www.umd.be/HSF/>). The frequency of this variant was checked in 1000 genome project, ExAC, and Iranome databases.

Ethical statement

The above-mentioned sampling protocols were approved by the Research Ethics Committee of Islamic Azad University, Tonekabon Branch, Tonekabon, Iran (Ethical code: IR.IAU.TON.REC.1399.031). Written informed consent was provided by all the participants in the study.

RESULTS

A novel splice site variant (c.860-2A>G) in the intron 6 of *RUNX2* gene was identified in the proband by Sanger sequencing. This variant probably will result in a premature stop codon and truncated protein. The variant was observed in the other affected members but was absent in the healthy individuals (Fig. 1D). We could not observe this variant in 100 healthy ethnicity-matched control individuals by ARMS-PCR. The variant was also absent in 1000 genome project, ExAC, and Iranome databases. Different online *in silico* prediction software such as MutationTaster, HSF, and VEP indicated that this variant is pathogenic.

DISCUSSION

To date, four types of CCD have been reported. The first type has typical clinical manifestations and is hereditary, the second one has typical clinical manifestations but is not hereditary, the third group has atypical clinical manifestations and is hereditary, and the fourth type has neither typical clinical manifestations nor a history of heredity^[10]. Herein, we observed typical clinical manifestations of CCD and

history of heredity through four generations in an Iranian family.

One of the prominent clinical findings in affected individuals with CCD is clavicular hypoplasia, which has also been reported in several other cytogenetic abnormalities^[5]. Translocations and duplications including 8q22^[11], partial trisomy 11q^[12], partial trisomy 11q/22q^[13], trisomy 20p^[14], and submicroscopic deletions occur in a small fraction of CCD patients^[15,16]. In this study, no cytogenetic abnormality was found in affected individuals.

While there is a wide range of clinical manifestations in CCD patients^[10], many other diseases resemble CCD^[17]; for instance, Pyknodysostosis (MIM 265800), a rare osteosclerosis disease characterized by malformations of sutures and fontanelles, Wormian bones, clavicular hypoplasia, short terminal phalanges, and tooth anomalies^[5]. The major clinical manifestations of mandibuloacral dysplasia (MIM 248370) are clavicular hypoplasia, Wormian bones, persistent cranial sutures, and dental problems. Patients suffering from Yunis-Varon syndrome (MIM 216340) also have clavicular hypoplasia.

The *RUNX* proteins are key regulators of bone formation^[17]. CCD is caused by haploinsufficiency of the *RUNX2* transcription factor^[16,18]. Mutations in *RUNX2* gene have high penetrance and extreme variability, ranging from isolated dental anomalies to fully manifesting disease with poorly ossified cranium and absence of clavicles^[10]. The significance of *RUNX2* is highlighted as a key regulatory factor in bone formation by studies on mice models. Mice carrying one disrupted *RUNX2* allele resembled the human CCD phenotype, including clavicular hypoplasia, and the homozygous *Runx2* mutant mice revealed disturbing bone formation due to the absence of ossification^[17]. Until now, over 100 different mutations^[19] have been reported in the *RUNX2* gene^[20-22], including missense, nonsense, splicing, and frame-shift variants in over 65% of CCD cases^[21-23]. In this study, a novel splice site mutation of c.860-2A>G in the *RUNX2* gene was identified. *RUNX2* contains several domains: (i) an N-terminal Q/A domain composed of a stretch of 23 consecutive glutamines, followed by 17 consecutive alanines, which the length of this domain is important for transcriptional activity^[24-26]; (ii) a RUNT domain, that has a unique ability of mediating DNA binding and protein heterodimerization; (iii) a C-terminal proline-serine-threonine-rich activation domain that can also mediate protein-protein interaction^[24] and it is essential for the transcriptional activity of *RUNX2* protein^[23]; (iv) the last five amino acids of the protein known as the VWPRY motif^[19].

The novel splice site variant, c.860-2A>G, in the *RUNX2* gene probably results in a frameshift in the reading frame after proline-serine-threonine-rich domain via exon skipping and eventually causes a premature stop codon. The intact VWRPY motif has been proposed to be crucial for the transcriptional repression activity of *RUNX2* protein via interaction with TLE proteins, which is essential for osteogenesis^[19]. Therefore, we can conclude that the c.860-2A>G splice site variant identified in our study will likely remove the VWRPY peptide sequence part of *RUNX2* due to the premature stop codon.

CCD disorder shows a broad spectrum of phenotypic variability ranging from cases who do not exhibit typical symptoms to classic clinical manifestations^[27]. In the current study, the classical manifestations of CCD patients have been detected in an Iranian family. Furthermore, a splice site mutation (c.860-2A>G) was found in the intron 6 of *RUNX2* gene in this family, which has not been reported before. Overall, clinical diagnosis can play a key role in identifying CCD patients and recommends that Sanger sequencing of *RUNX2* gene can be a rapid and cost-efficient diagnostic solution for CCD families who show classical manifestations of this disease.

ACKNOWLEDGMENTS

We are thankful to the patients and family members for their participation.

CONFLICT OF INTEREST. None declared.

REFERENCES

- Marie P, Sainton P. Sur la dysostose cleido-clanienne hereditaire. *Revista de Neurología* 1898; **6**: 835-838.
- Patil PP, Barpande SR, Bhavthankar JD, Humbe JG. Cleidocranial dysplasia: A clinico-radiographic spectrum with differential diagnosis. *Journal of orthopaedic case reports* 2015; **5**(2): 21-24.
- Keats TE. Cleidocranial dysostosis: some atypical roentgen manifestations. *The American journal of roentgenology radium therapy and nuclear medicine* 1967; **100**(1): 71-74.
- Jarvis JL, KEATS TE. Cleidocranial dysostosis: A review of 40 new cases. *American journal of roentgenology*. 1974; **121**(1): 5-16.
- Mundlos S. Cleidocranial dysplasia: clinical and molecular genetics. *Journal of medical genetics* 1999; **36**(3): 177-182.
- Rezani Toptancı İ, Çolak H, Köseoğlu S. Cleidocranial dysplasia: Etiology, clinicoradiological presentation and management. *Journal of clinical and experimental investigations* 2012; **3**: 133-136.
- Garg RK, Agrawal P. Clinical spectrum of cleidocranial dysplasia: a case report. *Cases journal* 2008; **1**(1): 377.
- Chelvan HT, Malathi N, Kailasam V, Ponnudurai A. Cleidocranial dysplasia: a family report. *Journal of the Indian society of pedodontics and preventive dentistry* 2009; **27**(4): 249-252.
- Li YL, Xiao ZS. Advances in Runx2 regulation and its isoforms. *Medical hypotheses* 2007; **68**(1): 169-175.
- Golan I, Preising M, Wagener H, Baumert U, Niederdelmann H, Lorenz B, Müssig D. A novel missense mutation of the *CBFA1* gene in a family with cleidocranial dysplasia (CCD) and variable expressivity. *Journal of craniofacial genetics and developmental biology* 2000; **20**(3): 113-120.
- Brueton LA, Reeve A, Ellis R, Husband P, Thompson EM, Kingston HM. Apparent cleidocranial dysplasia associated with abnormalities of 8q22 in three individuals. *American journal of medical genetics* 1992; **43**(3): 612-618.
- Francke U, Weber F, Sparkes RS, Mattson PD, Mann J. Duplication 11 (q21 to 23 leads to qter) syndrome. *Birth defects original article series* 1977; **13**(3b): 167-186.
- Nakai H, Yamamoto Y, Kuroki Y. Partial trisomy of 11 and 22 due to familial translocation t(11;22)(q23;q11), inherited in three generations. *Human genetics* 1979; **51**(3): 349-355.
- Schinzel A. Trisomy 20pter = to q11 in a malformed boy from a t(13;20)(p11;q11) translocation-carrier mother. *Human genetics* 1980; **53**(2): 169-172.
- Gelb BD, Cooper E, Shevell M, Desnick RJ. Genetic mapping of the cleidocranial dysplasia (CCD) locus on chromosome band 6p21 to include a microdeletion. *American journal of medical genetics* 1995; **58**(2): 200-205.
- Mundlos S, Mulliken JB, Abramson DL, Warman ML, Knoll JH, Olsen BR. Genetic mapping of cleidocranial dysplasia and evidence of a microdeletion in one family. *Human molecular genetics* 1995; **4**(1): 71-75.
- Komori T, Yagi H, Nomura S, Yamaguchi A, Sasaki K, Deguchi K, Shimizu Y, Bronson RT, Gao YH, Inada M, Sato M, Okamoto R, Kitamura Y, Yoshiki S, Kishimoto T. Targeted disruption of *Cbfa1* results in a complete lack of bone formation owing to maturational arrest of osteoblasts. *Cell* 1997; **89**(5): 755-764.
- Napierala D, Garcia-Rojas X, Sam K, Wakui K, Chen C, Mendoza-Londono R, Zhou G, Zheng Q, Lee B. Mutations and promoter SNPs in *RUNX2*, a transcriptional regulator of bone formation. *Molecular genetics and metabolism* 2005; **86**(1-2): 257-268.
- Ercan Sekerci A, Balta B, Bahadır O, Sisman Y, Dundar M, Tursem Tokmak T, Mundlos S. Cleidocranial dysplasia with a rare mutation: Study of a family with review of literature. *Open journal of stomatology* 2013; (03): 402-410.
- Machuca-Tzili L, Monroy-Jaramillo N, Gonzalez-del Angel A, Kofman-Alfaro S. New mutations in the *CBFA1* gene in two Mexican patients with cleidocranial dysplasia. *Clinical genetics* 2002; **61**(5): 349-353.
- Otto F, Kanegane H, Mundlos S. Mutations in the

- RUNX2* gene in patients with cleidocranial dysplasia. *Human mutation* 2002; **19**(3): 209-216.
22. Yoshida T, Kanegane H, Osato M, Yanagida M, Miyawaki T, Ito Y, Shigesada K. Functional analysis of *RUNX2* mutations in Japanese patients with cleidocranial dysplasia demonstrates novel genotype-phenotype correlations. *American journal of human genetics* 2002; **71**(4): 724-738.
 23. Zhang YW, Yasui N, Kakazu N, Abe T, Takada K, Imai S, Sato M, Nomura S, Ochi T, Okuzumi S, Nogami H, Nagai T, Ohashi H, Ito Y. PEBP2alphaA/CBFA1 mutations in Japanese cleidocranial dysplasia patients. *Gene* 2000; **244**(1-2): 21-28.
 24. Geoffroy V, Corral DA, Zhou L, Lee B, Karsenty G. Genomic organization, expression of the human CBFA1 gene, and evidence for an alternative splicing event affecting protein function. *Mammalian genome* 1998; **9**(1): 54-57.
 25. Mundlos S, Otto F, Mundlos C, Mulliken JB, Aylsworth AS, Albright S, Lindhout D, Cole WG, Knoll JH, Owen MJ, Mertelsmann R, Zabel BU, Oslen BR. Mutations involving the transcription factor CBFA1 cause cleidocranial dysplasia. *Cell* 1997; **89**(5): 773-779.
 26. Thirunavukkarasu K, Mahajan M, McLarren KW, Stifani S, Karsenty G. Two domains unique to osteoblast-specific transcription factor Osf2/Cbfa1 contribute to its transactivation function and its inability to heterodimerize with Cbfbeta. *Molecular and cellular biology* 1998; **18**(7): 4197-4208.
 27. Wang S, Zhang S, Wang Y, Chen Y, Zhou L. Cleidocranial dysplasia syndrome: clinical characteristics and mutation study of a Chinese family. *International journal of clinical and experimental medicine* 2013; **6**(10): 900-907.