

## The Morphological Changes of Adult Mouse Testes after $^{60}\text{Co}$ $\gamma$ -Radiation

Morteza Koruji<sup>1</sup>, Mansoureh Movahedin<sup>\*1</sup>, Seyed Javad Mowla<sup>2</sup>, Hamid Gourabi<sup>3</sup>  
and Ali Jabbari Arfaee<sup>4</sup>

<sup>1</sup>Dept. of Anatomical Sciences, School of Medical Sciences, Tehran; <sup>2</sup>Dept. of Genetics, School of Basic Sciences, Tarbiat Modarres University, Tehran; <sup>3</sup>Dept. of Genetics, Institute of Royan, Tehran; <sup>4</sup>Dept. of Radiation Oncology, Shohada-E-Tajrish Hospital, Tehran, Iran

Received 9 April 2007; revised 26 June 2007; accepted 1 July 2007

### ABSTRACT

**Background:** Cytotoxic therapy can lead to prolonged azoospermia or even sterility. In the present study, we investigated the morphological changes of mouse testes after  $\gamma$ -Radiation. **Methods:** After anaesthetizing of NMRI mice, testes and their surrounding tissues were irradiated using a cobalt therapy machine. Four experimental groups were irradiated with fractionated doses of: 1.5+8, 1.5+12 and 1.5+16 Gy (with an interval of 24 h) and single dose of 14 Gy. Non-irradiated mice were considered as control group. Testes were removed 4, 6 and 8 weeks following irradiation, weighed and processed for light microscopic study. Diameters of seminiferous tubules and their lumens, epithelium thickness, percentage of different types of tubules and number of spermatogenic cell were measured. Moreover, sperm count motility and viability rates were evaluated in epididymis. **Results:** Number of normal tubules, epithelium thickness, tubules diameter and lumen diameter were significantly reduced with high dose irradiation in comparison with control testes. The recovery was observed after 8 weeks. Epididymal sperm count, motility and viability rates were significantly decreased in the irradiated mice comparing non-irradiated ones. These parameters were increased after 8 weeks. **Conclusion:** According to the results, irradiation can cause temporary azoospermia in mouse and this effect is reversible after 8 weeks. *Iran. Biomed. J. 12 (1): 35-42, 2008*

*Keywords:*  $\gamma$ -radiation, Mouse testis, Morphology

### INTRODUCTION

There are two different types of radiation: energetic particles and electromagnetic waves. These two types can penetrate into living tissues or cells and result in transduction of radiation energy to biological materials. The absorbed energy of ionizing radiation can break chemical bonds and cause ionization of different molecules including water and different biological essential macromolecules as DNA [1, 2], membrane lipids and proteins [3, 4]. Many types of DNA lesions are produced in cells by ionizing radiation and chemicals during cancer therapy [5], which can induce spermatogenesis defects. Nowadays, many children and young adults are successfully treated for several types of cancer. However, these

treatments cause permanent or long-lasting infertility [6]. Recently, testicular cell transplantation has been widely used to investigate restoration of spermatogenesis in various species. One of the critical steps in successful transplantation is preparation of the recipient testes [7, 8]. For this purpose, maximal depletion of endogenous germ cells and emptying stem cell niches with minimal damage to the local spermatogenic and systemic environment are required [8]. Several approaches are used to deplete testicular germ cells from immature and adult animals [9, 10], including treatment with cytotoxic agents such as busulfan, radiation, induction of cryptorchidism, hyper- or hypothermia, ischemia and vitamin A deficiency. Busulfan can effectively deplete the majority of spermatogonial cells after 1 or 2 intraperitoneal injections [8, 11]

\*Corresponding Author; Tel. (+98-21) 8801 1001 (Ext. 4502); Fax: (+98-21) 8801 3030; E-mail: mansoureh@modares.ac.ir

and it has been used to produce recipient testes for germ cell transplantation [12, 13], but its myelogenic toxicity usually has an adverse effect on the health of treated animals, and bone marrow transplantation may require [14, 15]. Localized radiation treatment is a useful tool in this regard because of its efficiency at killing endogenous stem cells in mouse testes. A number of radiation treatment protocols have been tested and used for testis depletion of several species [16-18] but the effectiveness of testicular irradiation with  $^{60}\text{Co}$   $\gamma$ -ray for preparing azoospermic model has not been evaluated yet. The aim of the present study was to investigate the morphological changes of adult mouse testes following gamma ray irradiation and its efficiency in azoospermic mouse model preparation.

## MATERIALS AND METHODS

**Animals.** Adult NMRI mice (6-8 weeks old) were obtained from Razi Vaccine and Serum Research Institute (Karaj, Iran). Animals were anaesthetized with ketamine/xylazine (Alfasan, Woerden, Netherlands, 100 mg/kg: 10 mg/kg) mixture and the pelvic and lower limbs of the mice were radiated with  $^{60}\text{Co}$   $\gamma$ -ray from cobalt therapy machine (Shohada-E-Tajrish Hospital, Tehran, Iran). Dose rate was 1.37 Gy/min and the remainder of the body was shielded with lead plate. Mice were irradiated with single doses of 14 and a two-day fractionated doses ionizing radiation protocol; in which a dose of 1.5 Gy was followed by doses of: 8, 12 and 16 Gy (with an interval of 24 h). Also, 25 Gy was considered as lethal dose. The low dose and high dose were selected based on pilot study in mice. Mobilization of testis to the scrotum was prevented by the crosswise application of tape to the lower abdomen. Irradiated and control animals were sacrificed by cervical dislocation 4, 6 and 8 weeks after irradiation. Following cervical dislocation, left testis was recovered, weighed and fixed in Bouin fixative, dehydrated and embedded in paraffin. Then, 5- $\mu\text{m}$  serial microscopic sections were prepared and at least 5 slides from each testis were stained with hematoxylin and eosin for histological assessment [19]. In each experiment, at least 3 animals were received irradiation and analyzed for each dose and time point. All animal experimentation protocols were approved by Institutional Animal Care and Use Committee of Tarbiat Modarres University, Tehran, Iran.

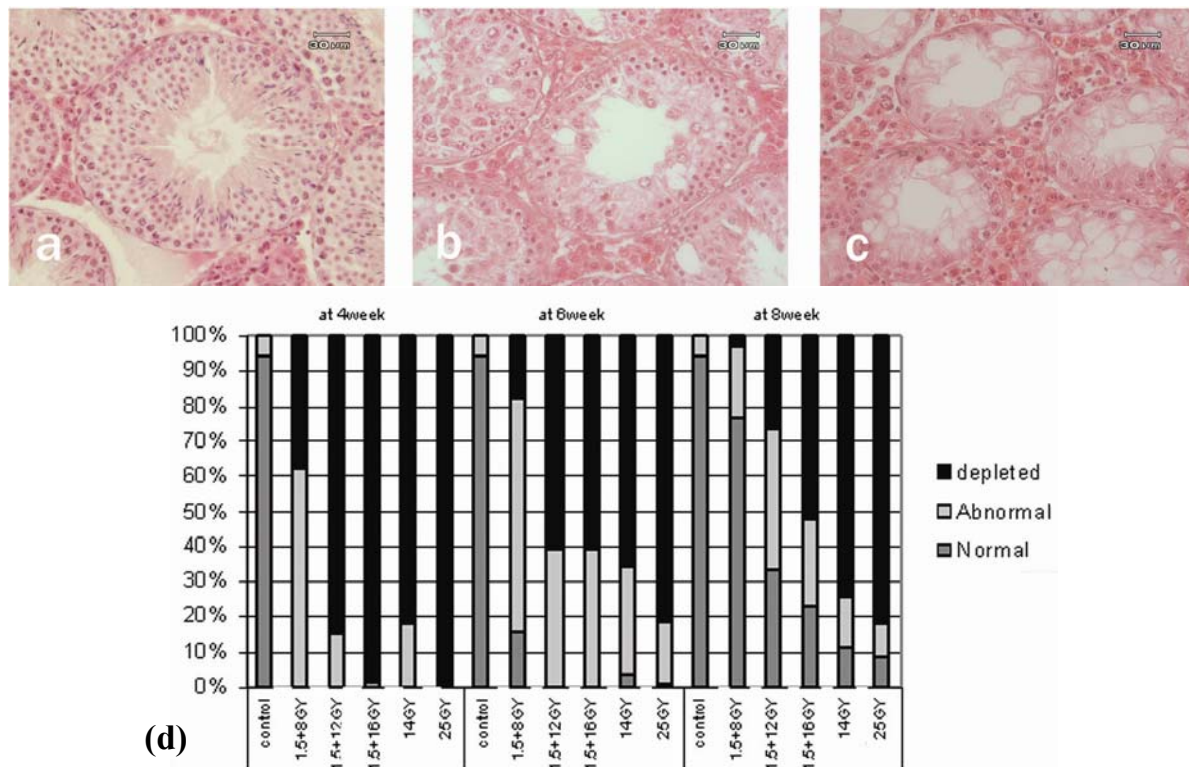
**Sperm parameters assessment.** Sperm parameters were assessed using a procedure described by Velojerdi *et al.* [20]. The mouse epididymis was removed and placed in 1 ml PBS at pH 7.4 and minced into small pieces before being incubated at 37°C for 30 min. Sperm parameters were monitored by light microscopy and its viability was assessed by determining the percentage of sperms excluding vital dye (0.5% Eosin B solution). Briefly, 7  $\mu\text{l}$  of eosin solution was added to 20  $\mu\text{l}$  of cell suspension after incubation and mixed thoroughly. Eosin stained the head of dead sperms but did not penetrate the membrane of living cells, which remained unstained. Motility of sperm was also assessed by determining the percentage of progressive motile sperm. Finally, sperm number was also calculated with a hemacytometer (NEUBAUER Improved HBG Company, Germany) and compared in both irradiated and control groups.

**Morphometrical analysis of testis.** An ocular grid was used to measure the diameter of seminiferous tubules, diameter of lumen and seminiferous height epithelium. Also, for each testis, in 100 randomly selected tubular profiles that were round or nearly round, the percentage of 3 types of tubules: normal seminiferous tubule with sperm (type 1), normal seminiferous tubules without sperm (type 2) and depleted seminiferous tubule (type 3) as well as the diameters of the tubules and epithelium thickness were measured using light microscopy (Fig. 1a-c). Using a 441-intersection grid, volume density of spermatogonial cells, spermatocytes and spermatids in seminiferous tubules were determined [21-23]. The location and morphology of the cells within the seminiferous tubules were used to identify them. An estimate of each parameter was performed by examining 15 fields in 5 histological sections from each testis.

**Statistical analysis.** The results were analyzed by performing two-way analysis variance and Tukey's tests.  $P < 0.05$  considered as statistically significant and mean  $\pm$  SD was also calculated for each value.

## RESULTS

**Assessment of sperm parameters.** According to our data, there is a significant decline in sperm's viability and motility rates (Table 1) as well as in



**Fig. 1.** Histological examination and percentage of three type seminiferous tubules cross-section in mouse testes following  $^{60}\text{Co}$   $\gamma$ -Radiation. (a), normal seminiferous tubule with sperm (normal); (b), normal seminiferous tubule without sperm (abnormal); (c), abnormal seminiferous tubule without germ cells (depleted); (d), percentage of three type seminiferous tubules. H and E staining.

number of sperms (Table 2) following  $^{60}\text{Co}$   $\gamma$ -Radiation. The declines in the sperm viability and statistically significant comparing to 6<sup>th</sup> and 8<sup>th</sup> week motility rates in the 4<sup>th</sup> week groups were groups (Table 1). At 4<sup>th</sup> week, the doses of 1.5 + 8, 1.5 + 12, 1.5 + 16 and 14 Gy resulted in a significant decline in sperm's viability ( $32.6 \pm 4.08\%$ ,  $23.5 \pm 4.8\%$ ,  $25.5 \pm 2.8\%$ ,  $19.5 \pm 6\%$ ) and motility ( $0.14 \pm 0.24\%$ ,  $0 \pm 0\%$ ,  $0 \pm 0\%$ ,  $0 \pm 0\%$ ) rates, respectively, comparing with control group (viability rate:  $75.3 \pm 4.5\%$  and motility rate:  $71.7 \pm 1.5\%$ ). Meanwhile, at

all doses of irradiation, viability ( $54.5 \pm 11$ ,  $39.6 \pm 2.9$ ,  $22.2 \pm 6.8$ ,  $0 \pm 0$ ) and motility ( $28.7 \pm 8.1$ ,  $7.7 \pm 4.2$ ,  $5 \pm 1$ ,  $0 \pm 0$ ) rates increased at 8<sup>th</sup> week. Taken together, differences of viability and motility rates at dose of 14 Gy were not statistically significant comparing with dose of 1.5 + 16 Gy. At the same above doses, numbers of sperms significantly declined at 4<sup>th</sup> week ( $0.61 \pm 0.04 \times 10^6$ ,  $0.27 \pm 0.1 \times 10^6$ ,  $0.04 \pm 0.01 \times 10^6$ ,  $0.084 \pm 0.008 \times 10^6$ , respectively,) comparing with control group ( $4.42 \pm 0.027 \times 10^6$ ) and increased at 8<sup>th</sup> week. As presented

**Table 1.** Viability and motility rates (%) of sperms aspirated from epididymis after  $^{60}\text{Co}$   $\gamma$ -Radiation.

Sperm parameters Time of assessment	Viability rate (mean $\pm$ SD)			Motility rate (mean $\pm$ SD)		
	4 <sup>th</sup> w	6 <sup>th</sup> w	8 <sup>th</sup> w	4 <sup>th</sup> w	6 <sup>th</sup> w	8 <sup>th</sup> w
Control	$75.3 \pm 4.50^a$	$78.0 \pm 3.0^a$	$75.0 \pm 2.0^a$	$71.70 \pm 1.50$	$70.7 \pm 2.5$	$75.0 \pm 6.0$
1.5 + 8 GY	$32.6 \pm 4.08^{ac*}$	$34.2 \pm 3.8^{ac*}$	$54.5 \pm 11.0^a$	$0.14 \pm 0.24^{ac}$	$3.7 \pm 4.6^{ac}$	$28.7 \pm 8.1^a$
1.5 + 12 GY	$23.5 \pm 4.80^{ac}$	$21.6 \pm 3.5^{abc**}$	$39.6 \pm 2.9^a$	$0.00 \pm 0.00^{ac*}$	$0.0 \pm 0.0^{ac*}$	$7.7 \pm 4.2^{ab}$
1.5 + 16 GY	$25.5 \pm 2.80^a$	$19.9 \pm 3.5^{ab}$	$22.2 \pm 6.8^{abc}$	$0.00 \pm 0.00^{ac}$	$0.0 \pm 0.0^{ac**}$	$5.0 \pm 1.0^{ab}$
14 GY	$19.5 \pm 6.00^{abc**}$	$0.0 \pm 0.0^{abcd}$	$0.0 \pm 0.0^{abcd}$	$0.00 \pm 0.00^a$	$0.0 \pm 0.0^a$	$0.0 \pm 0.0^{ab}$

The replication of experiences was at least 3 times for all groups. a, significant difference versus control group in the same column ( $P < 0.001$ ); b, significant difference versus 1.5 + 8 GY dose of irradiation in the same column ( $P < 0.001$ ); c, difference versus 1.5 + 12 GY dose of irradiation in the same column ( $P < 0.001$ ); d, difference versus 1.5 + 16 GY dose of irradiation in the same column ( $P < 0.00$ ); e, significant difference versus w8 in the same row ( $P < 0.05$  and  $P < 0.01$ ); f, significant difference versus w4 in the same row ( $P < 0.001$ ). SD, standard deviation; \* $P < 0.05$ , \*\* $P < 0.01$ .

**Table 2.** Sperm count per ml in epididymis after  $^{60}\text{Co}$   $\gamma$ -Radiation.

Time of assessment	Sperm count (mean $\pm$ SD) $\times 10^6$		
	4 <sup>th</sup> w	6 <sup>th</sup> w	8 <sup>th</sup> w
Control	4.420 $\pm$ 0.027 <sup>a</sup>	4.510 $\pm$ 0.076 <sup>a</sup>	4.13 $\pm$ 0.20 <sup>a</sup>
1.5 + 8 Gy	0.610 $\pm$ 0.040 <sup>a</sup>	2.080 $\pm$ 0.600 <sup>ac**</sup>	2.30 $\pm$ 0.17 <sup>ac**</sup>
1.5 + 12 Gy	0.270 $\pm$ 0.100 <sup>a</sup>	0.006 $\pm$ 0.001 <sup>abc*</sup>	0.16 $\pm$ 0.09 <sup>ab</sup>
1.5 + 16 Gy	0.040 $\pm$ 0.010 <sup>ab</sup>	0.029 $\pm$ 0.002 <sup>ab</sup>	0.02 $\pm$ 0.01 <sup>ab</sup>
14 Gy	0.084 $\pm$ 0.008 <sup>ab</sup>	0.000 $\pm$ 0.000 <sup>abc***</sup>	0.00 $\pm$ 0.00 <sup>abc***</sup>

The replication of experiences was at least 3 times for all groups. a, significant difference versus control group in the same column ( $P < 0.001$ ); b, significant difference versus 1.5 + 8 Gy dose of irradiation in the same column ( $P < 0.001$ ); c, significant difference versus w4 in the same row. SD, standard deviation; \* $P < 0.05$ ; \*\* $P < 0.01$ ; \*\*\* $P < 0.01$ .

in Table 2, all doses of irradiation significantly decreased the number of sperms less than critical number ( $< 6.5 \times 10^5 \pm 9 \times 10^3$  sperm/ml) [24]. Sperm count at low dose of irradiation (1.5 + 8 Gy) was reversible and reached to  $2.3 \pm 0.17 \times 10^6$  sperm/ml at 8<sup>th</sup> week.

#### Assessment of morphological changes.

According to our results, the 25 Gy dose of  $^{60}\text{Co}$   $\gamma$ -Radiation was lethal for mouse because the dose of 25 Gy was resulted lesions in tubule architecture and skin characterized by erythema and transudation (in 84% irradiated animals). This regimen was not pursued for further study.

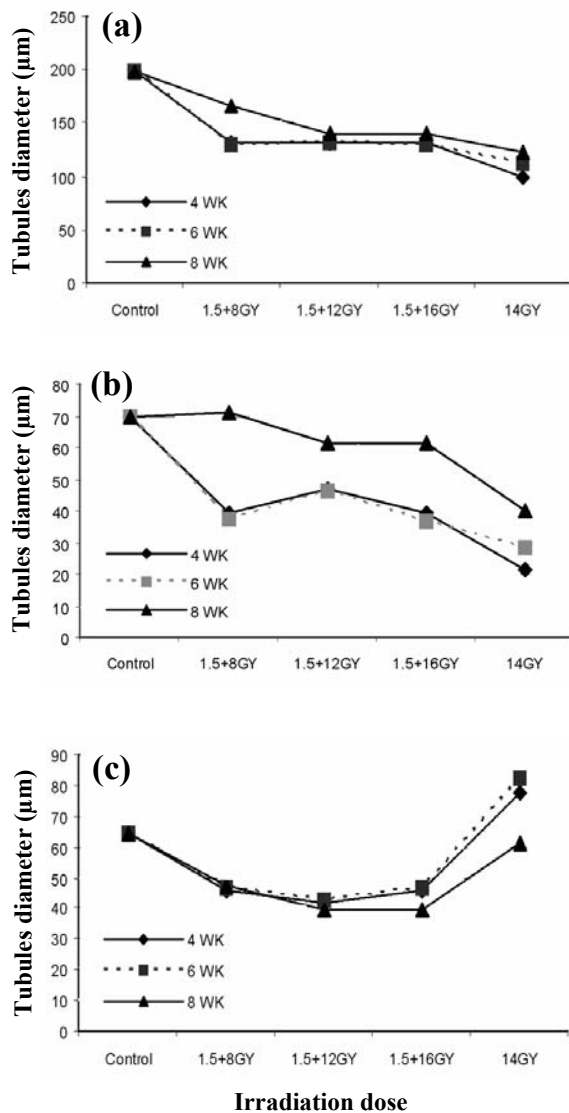
At 4<sup>th</sup> week, testicular weights in the irradiated groups (1.5 + 8, 1.5 + 12, 1.5 + 16 and 14 Gy) were significantly less than (0.08  $\pm$  0.01, 0.04  $\pm$  0.01, 0.037  $\pm$  0.005, 0.25  $\pm$  0.005 g) the control group (0.19  $\pm$  0.02 g). The decrease in the weights of treated testes was irreversible at the 8<sup>th</sup> week after irradiation (0.08  $\pm$  0.0, 10.06  $\pm$  0.03, 0.04  $\pm$  0.02, 0.042  $\pm$  0.003) (Table 3). Measuring seminiferous tubules diameter and epithelium height at different times showed the maximum effect of irradiation at 4<sup>th</sup> week (Fig. 2). Also, dose of 14 Gy showed maximum effects on tubules structure ( $98.9 \pm 16.3$   $\mu\text{m}$ ). We also determined the percentage of the 3

types of seminiferous tubules in the cross-sections of testes in control and treatment groups. Histological analysis of testes indicated that the maximum number of depleted seminiferous tubules were seen at dose of 14 Gy (76.6%) and 1.5 + 16 Gy (51.3%) at 8<sup>th</sup> week. Further histological analysis of animals' testes treated with irradiation revealed that most testes contained depleted tubules at 4<sup>th</sup> week groups [1.5 + 8 (38  $\pm$  12.5%), 1.5 + 12 (84.7  $\pm$  7.02%), 1.5 + 16 (98  $\pm$  3.5%), 14 (82.6  $\pm$  1.9%)], but some regeneration occurred in some tubules later (Fig. 1d). On the other hand, spermatogenesis regeneration was dose-dependent and it was seen significantly in irradiated mice affected with low dose of 1.5 + 8 Gy (77.3  $\pm$  10%). seminiferous tubules (32.3% , 22.3% and 11.2%) which affected respectively with 1.5 + 12, 1.5 + 16 and 14 Gy irradiation also showed apparently normal spermatogenesis with mature spermatozoa 8 weeks after irradiation. Irradiation also resulted in a significant dose-dependent decrease in the number of spermatogenic cells (spermatogonia, spermatocytes and spermatid) in the seminiferous tubules. The maximum effects of irradiation were seen at 4<sup>th</sup> weeks after irradiation when seminiferous tubules were mostly vacant of germ cells. However, a comparative count of spermatocytes

**Table 3.** Testicular weights (g) in the after  $^{60}\text{Co}$   $\gamma$ -Radiation.

Time of assessment	Testicular weights (mean $\pm$ SD)		
	4 <sup>th</sup> w	6 <sup>th</sup> w	8 <sup>th</sup> w
Control	0.130 $\pm$ 0.010	0.170 $\pm$ 0.030	0.190 $\pm$ 0.020
1.5 + 8 Gy	0.080 $\pm$ 0.010 <sup>a</sup>	0.080 $\pm$ 0.030 <sup>a**</sup>	0.080 $\pm$ 0.010 <sup>a</sup>
1.5 + 12 Gy	0.040 $\pm$ 0.010 <sup>ab</sup>	0.050 $\pm$ 0.005 <sup>a</sup>	0.060 $\pm$ 0.030 <sup>a</sup>
1.5 + 16 Gy	0.037 $\pm$ 0.005 <sup>ab**</sup>	0.066 $\pm$ 0.005 <sup>a</sup>	0.040 $\pm$ 0.020 <sup>a</sup>
14 Gy	0.0250 $\pm$ 0.005 <sup>abc</sup>	0.030 $\pm$ 0.008 <sup>a</sup>	0.042 $\pm$ 0.0030 <sup>a</sup>

The replication of experiences was at least 3 times for all groups. a, significant difference versus control group in the same column ( $P < 0.001$ ); b, significant difference versus 1.5 + 8 Gy dose of irradiation in the same column ( $P < 0.001$ ); c, significant difference versus w8 ( $P < 0.05$ ). \*\* $P < 0.01$ .



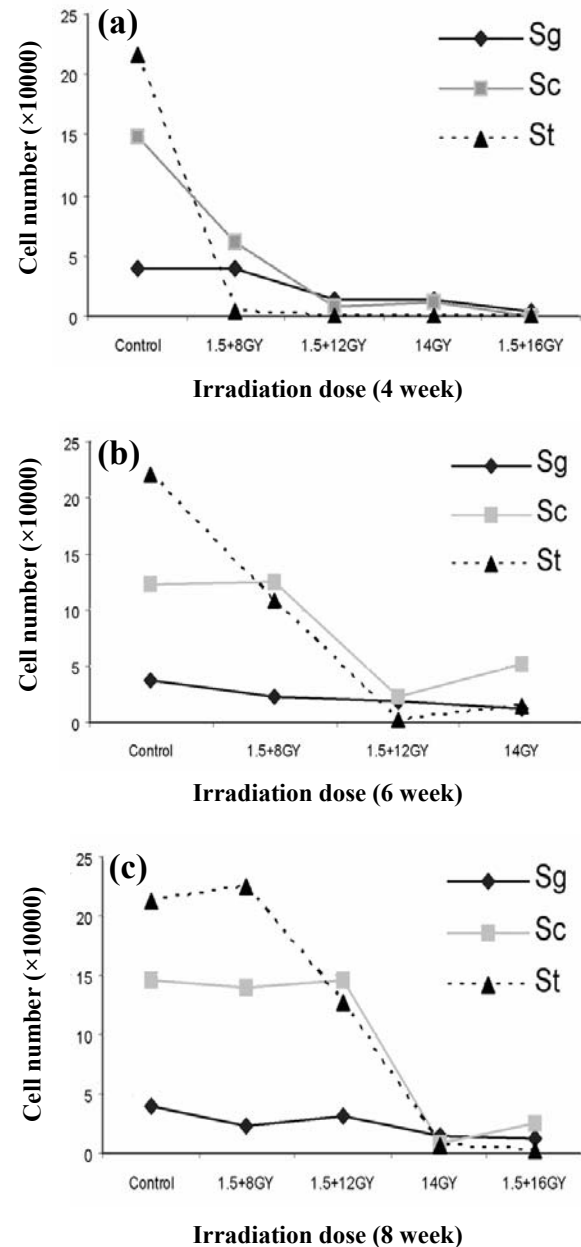
**Fig. 2.** Histological examination of seminiferous tubules diameter, lumen diameter and epithelium thickness in mouse testes following irradiation. (a), seminiferous tubules diameters ( $\mu\text{m}$ ), (b), seminiferous lumen diameters ( $\mu\text{m}$ ); (c), epithelium thickness ( $\mu\text{m}$ ).

and spermatids at different time groups suggests that the irradiation effect is dose-dependent and reversible (Fig. 3). During the 4<sup>th</sup> week after irradiation almost for all doses, the seminiferous tubules solely contained Sertoli cells.

## DISCUSSION

In the present study, we have determined the extent of changes in mouse testis structure and epididymal sperms parameters following  $^{60}\text{Co}$   $\gamma$ -

Radiation. To accomplish this, we have used different doses as well as different time points of irradiation to evaluate the effects of  $^{60}\text{Co}$   $\gamma$ -Radiation on spermatogenesis. We used radiation treatment, which has been demonstrated to be an efficient method for germ cell depletion, while also avoiding the complications of systemic drug treatments such as busulfan, a DNA alkylating agent that destroys



**Fig. 3.** Cell count per ( $\text{mm}^3$ ) in seminiferous tubules (mean  $\pm$  SD)  $\times 10^4$  in mouse testes following after  $^{60}\text{Co}$   $\gamma$ -Radiation. (a), spermatogonial; (b), spermatocyte and (c), spermatid cells count per ( $\text{mm}^3$ ) in seminiferous tubules.

proliferating cells. Busulfan can therefore affect proliferating cells elsewhere in the body, such as in the bone marrow, as well as endogenous germ cells [14, 15].

The main rational reasons to choose 4-week-time were: firstly, the length of time from initiation of stem cell division to formation of spermatozoa is around 33 days in mouse [25]; secondly, we give the Sertoli cells the opportunity to remove dead germ cells and increase access to stem cell niches along the basement membrane after irradiation and thirdly, if transplantation was performed for the purpose of breeding with donor-derived sperm, then there would be a desire to have as long a lifespan as possible post-procedure so that sperm could be collected over the time period required [9]. The chosen period of time (6 and 8 weeks) provided sufficient time to monitor the potential recovery of spermatogenesis in surviving stem cells in the irradiated animals.

The epididymal sperm analysis indicated that high-dose irradiation eliminates sperm number and declines their viability and motility rates more significantly in epididymal lumen and makes animals longer sterile. Duration of sterility following  $^{60}\text{Co}$   $\gamma$ -Radiation treatments is dependent on the extent of stem cells. The surviving stem cells could repopulate the seminiferous epithelia and entire spermatogenic cell population after irradiation [26, 27]. Our data also revealed that firstly, the effects of irradiation are, to some extent, dose-dependent and reversible; secondly, the current radiation protocol depleted most of the spermatogonia but didn't destroy the ability of those that remained to complete spermatogenesis, nor did it destroy the ability of the Leydig cell and Sertoli cell populations to support spermatogenesis. Our result is in agreement with Kashiwabara *et al.* [28] and Kim *et al.* [9]. After radiation treatments at all doses except 1.5 + 8 Gy, very little testicular spermatozoa were released in the epididymal lumen, however 8 weeks after irradiation with 1.5 + 8 Gy, animals showed some degree of spermatogenesis restoration. Nevertheless, the animals were still infertile (expect dose of 1.5 + 8 Gy), based on their sperm analysis. According to the previous reports [9, 28], radiation treatment seems to produce only a non-permanent sterility, and the effects of irradiation on sperm parameters were somehow reversible [9].

In addition to sperm parameters, both seminiferous tubule type and weight testis are good predictors of fertility status. In this research, histological examination of seminiferous tubule showed

reversible spermatogenic cells loss. As has been previously reported, mice that received a lower dosage of irradiation may have some tubule repopulation from endogenous stem cells [28, 16, 9]. Our results showed that at doses of 14 Gy and 1.5 + 16 Gy, most tubules devoid of germ cells and contained only a single, basal row of nuclei. The remaining tubular content was eosinophilic and acellular in irradiated animals at high dose, and the regeneration occurred in a few tubules, some of these normal tubule show active spermatogenesis. We have also shown that depleted seminiferous tubules had only a single layer of cells attached to the tubular basal lamina. This finding is in agreement with the previous reports documenting the degenerative effects of irradiation on spermatogenesis in bovine, mouse and rat [16, 29, 30]. These results were similar to the following previous studies. Creemers *et al.* [16] depleted mouse testes using local fractionated X-irradiation. Their method resulted in >95% of empty tubules after 21 week of irradiation without any apparent effect on the somatic Sertoli cells. Izadyar *et al.* [18] irradiated calves with single graded doses of 10-14 Gy using 6MV X-rays. After irradiation, about 60% of tubules was empty at 5 months. These varied results show that species, dosage and regimen, the age of the subject and kind of rays might have significant effects on the long-term outcome of treatment.

At all doses, irradiated testes were smaller than untreated ones. Histological examinations of the testes in both control and irradiated groups revealed that the diameter of seminiferous tubules, diameter of lumen and seminiferous epithelium height were decreased significantly in all doses of treatment and the decreases were dose-dependent. Irradiated adult testis showed that diameters of testis and lumens decreased and probably this change were resulted from spermatogenic cell loss and tubules disorganization [16].

In general, approximately at least 50% of the seminiferous tubules must contain spermatogenesis for a mouse to be considered as fertile [30], so all the irradiated groups in our study are considered fertile in 8<sup>th</sup> week except for 14 Gy dose group. On the other hand, regeneration of spermatogenesis was more significant in animals receiving the  $^{60}\text{Co}$   $\gamma$ -Radiation at lower doses (1.5 + 8 Gy). There could be concordance between our finding and those reported previously [16, 18]. Interestingly, the improvement of decreased tubular diameters and epithelium height were not occurred as late as 8

weeks after irradiation, probably due to the fact that the regeneration of stem cells is a very slow process [25]. At higher doses, tubular cross-sections showed only some spermatogonia or none so a significant proportion of spermatogonial stem cells were eliminated at these doses. These findings confirm the results of an earlier study [26, 27] in which it was shown that undifferentiated type A spermatogonia was resistant to irradiation and could repopulate the seminiferous epithelia and entire spermatogenic cell population after irradiation. Following the depletion of differentiating spermatogonia, the ratio between surviving stem cells and differentiating cells could be significantly varied depending on the dosage, which may affect the self-renewal property of surviving stem cells, as suggested previously [31].

In conclusion, the present study provides detailed information on the effects of  $^{60}\text{Co}$   $\gamma$ -radiation treatment on the testicular and epididymal parameters. The information has the potential to increase its efficiency to make a reliable infertile recipient animal for germ cell transplantation technology. Also, it increases the success of colonization by opening up the appropriate "niches" for the transplanted spermatogonial stem cells [32], and it improves the relative yield of donor-derived versus recipient-derived sperm.

#### ACKNOWLEDGMENTS

We highly appreciate from Shahram Pour Beiranvand and Saeedeh Ebrahimi (Anatomical Sciences Department, Faculty of Medical Sciences, Tarbiat Modarres University, Tehran, Iran) for their technical assistances. This work was supported by a research grant from Tarbiat Modarres University.

#### REFERENCES

- Schulte-Frohlinde, D. and Bothe, E. (1991) The development of chemical damage of DNA in aqueous solution. In: *The Early Effects of Radiation in DNA* (Fielden, E.M. eds.), Springer, Berlin. pp. 317-332.
- Lett, J.T. (1992) Damage to cellular DNA from particulate radiation, the efficacy of its processing and the radiosensitivity of mammalian cells. Emphasis on DNA strand breaks and chromatin break. *Radiat. Environ. Biophys.* 31: 257-277.
- Cramp, W.A., Yatvin, M.B. and Harms-Ringdahl, M. (1994) Recent developments in the radiobiology of cellular membranes. *Acta Oncol.* 33: 945-952.
- Daniniak, N. and Tann, B.J. (1995) Utility of biological membranes as indicators for radiation exposure: alterations in membrane structure and function over time. *Stem Cells* 13: 142-152.
- Somosy, Z. (2000) Radiation response of cell organelles. *Micron* 31: 165-181.
- Izadyar, F., Creemers, L.B., Van Dissel-Emiliani, F.M.F., Van Pelt, A.M.M. and de Rooij, D.G. (2000) Spermatogonial stem cell transplantation. *Mol. Cell Endocrinol.* 169: 21-26.
- Ogawa, T., Dobrinski, I. and Brinster, R.L. (1999) Recipient preparation is critical for spermatogonial transplantation in the rat. *Tissue Cell* 31: 461-472.
- Brinster, C.J., Ryu, B.Y., Avarbock, M.R., Karagenc, L., Brinster, R.L., and Orwig, K.E. (2003) Restoration of fertility by germ cell transplantation requires effective recipient preparation. *Biol. Reprod.* 69: 412-420.
- Kim, Y., Selvaraj, V., Dobrinski, I., Lee, H., McEntee, M.C. and Travis, A.J. (2006) Recipient preparation and mixed germ cell isolation for spermatogonial stem cell transplantation in domestic cats. *J. Androl.* 27 (2): 248-256.
- Zhang, Z., Shao, S. and Meistrich M.L. (2006) Irradiated mouse testes efficiently support donor spermatogenesis from mice and rats. *J. Androl.* 27: 365-375.
- Jiang, F.X. (1998) Behavior of spermatogonia following recovery from busulfan treatment in the rat. *Anat. Embryol. (Berl)* 198: 53-61.
- Brinster, R.L. and Avarbock, M.R. (1994) Germline transmission of donor haplotype following spermatogonial transplantation. *Proc. Natl. Acad. Sci. USA* 91: 11303-11307.
- Jiang, F.X. and Short, R.V. (1995) Male germ cell transplantation in rats: apparent synchronization of spermatogenesis between host and donor seminiferous epithelia. *Int. J. Androl.* 18: 326-330.
- Clouthier, D.E., Avarbock, M.R., Maika, S.D., Hammer, R.E. and Brinster R.L. (1996) Rat spermatogenesis in mouse testis. *Nature* 381: 418-421.
- Ogawa, T., Dobrinski, M. and Brinster, R. (1999) Xenogeneic spermatogenesis following transplantation of hamster germ cells to mouse testes. *Biol. Reprod.* 60: 515-521.
- Creemers, L.B., Meng, X., Den Ouden, K., Van Pelt, A.M.M., Izadyar, F., Santoro, M., Sariola, H. and De Rooij, D.G. (2002) Transplantation of germ cells from glial cell line-derived neurotrophic factor over-expressing mice to host testes depleted of endogenous spermatogenesis by fractionated irradiation. *Biol. Reprod.* 66: 1579-1584.
- Schlatt, S., Foppiani, L., Rolf, C., Weinbauer, G.F. and Nieschlag, E. (2002) Germ cell transplantation into X-irradiated monkey testes. *Hum. Reprod.* 17: 55-62.
- Izadyar, F., Den Ouden, K., Stout, T.A.E., Stout, J.,

- Coret, J., Lankveld, D.P.K., Spoormakers, T.J.P., Colenbrander, B.C., Oldenbroek, J.K., Van Der Ploeg, K.D., Woelders, H., Kal, H.B. and De Rooij, D.G. (2003) Autologous and homologous transplantation of bovine spermatogonial stem cells. *Reproduction* 126: 765-774.
19. Anjamrooz, S.H., Movahedin, M., Mowla S.J. and Pour Bairanvand, S. (2007) Assessment of morphological and functional changes in the mouse testis and epididymal sperms following busulfan treatment. *Iran. Biomed. J.* 11: 15-22.
20. Velojerdi, M.R. (2003) Intracytoplasmic sperm injection ICSI. Boshra Ltd., Tehran, Iran.
21. Johnson, L. and Neaves, W.B. (1981) Age-related changes in the Leydig cell populations, seminiferous tubules and sperm production in stallions. *Biol. Reprod.* 24: 703-712.
22. Neves, E.S., Chiarini-Garcia, H. and Franc, L.R. (2002) Comparative testis morphometry and seminiferous epithelium cycle length in donkeys and mules. *Biol. Reprod.* 67: 247-255.
23. Franca, L.R. and Godinho, C.L. (2003) Testis morphometry, seminiferous epithelium cycle length, and daily sperm production in domestic cats (*Felis catus*). *Biol. Reprod.* 68: 1554-1561.
24. Bucci, L.R. and Meistrich, M.L. (1987) Effects of busulfan on murine spermatogenesis: cytotoxicity, sterility, sperm abnormalities, and dominant lethal mutations. *Mutat. Res.* 178: 259-268.
25. De Rooij, D.G. and Russell, L.D. (2000) All you wanted to know about spermatogonia but were afraid to ask. *J. Androl.* 1: 776-798.
26. Van Beek, M.E., Meistrich, M.L. and De Rooij, D.G. (1990) Probability of self-renewing divisions of spermatogonial stem cells in colonies, formed after fission neutron irradiation. *Cell Tissue Kinet.* 23: 1-16.
27. Van Der Meer, Y., Huiskamp, R., Davids, J.A., Van Der Tweel, I. and De Rooij, D.G. (1992) The sensitivity to X rays of mouse spermatogonia that are committed to differentiate and of differentiating spermatogonia. *Radiat. Res.* 130: 296-302.
28. Kashiwabara, S., Kashimoto, N., Sanoh, S., Uesaka, T., Katoh, O. and Watanabe, H. (2003) Damage of the mouse testis by tritiated water and <sup>137</sup>Cs-gamma-rays. *Hiroshima J. Med. Sci.* 52 (3): 53-58.
29. Van Pelt, A.M.M, Roepers-Gajadien, H.L., Gademan, I.S., Creemers, L.B., De Rooij, D.G. and Van Dissel-Emiliani, F.M. (2002) Establishment of cell lines with rat spermatogonial stem cell characteristics. *Endocrinology* 143: 1845-1850.
30. Izadyar, F., Matthijs-Rijnsenbilt, J.J., Den Ouden, K., Creemers, L.B., Woelders, H. and De Rooij, D.G. (2002) Development of a cryopreservation protocol for type A spermatogonia. *J. Androl.* 23: 537-545.
31. Kanatsu-Shinohara, M., Toyokuni, S., Morimoto, T., Matsui, S., Honjo, T. and Shinohara, T. (2003) Functional assessment of self-renewal activity of male germ line stem cells following cytotoxic damage and serial transplantation. *Biol. Reprod.* 68: 1801-1807.
32. Spradling, A., Drummond-Barbosa, D. and Kai, T. (2001) Stem cells find their niche. *Nature* 414: 98-104.