

# Protective Effects of Crocin against Cisplatin-Induced Acute Renal Failure and Oxidative Stress in Rats

Bahareh Naghizadeh<sup>\*1</sup>, Mohammad Taher Boroushaki<sup>2</sup>, Nasser Vahdati Mashhadian<sup>3</sup> and Seyed Mohammad Taghi Mansouri<sup>1</sup>

<sup>1</sup>Dept. of Pharmacology, Physiology Research Center, Faculty of Medicine, Ahvaz Jondishapour University of Medical Sciences, Ahvaz; <sup>2</sup>Dept. of Pharmacology and Pharmacological Research Center on Medicinal Plants, Faculty of Medicine, Mashhad University of Medical Sciences, Mashhad; <sup>3</sup>Dept. of Pharmacodynamics and Toxicology, Faculty of Pharmacy, Mashhad University of Medical Sciences, Mashhad, Iran

Received 6 December 2006; revised 12 August 2007; accepted 19 August 2007

## ABSTRACT

**Background.** The major side effect of cisplatin, used in some tumours, is nephrotoxicity. Reactive oxygen species and oxidative damage are the most important factors in cisplatin-induced acute renal failure. The main purpose of this study is to investigate the protective effects of crocin against cisplatin-induced acute renal failure and oxidative stress in rat. **Methods.** In this study, animals were randomly divided into 5 groups (6 each). Group one received normal saline (2 ml/day, i.p.). Group two received a single dose of cisplatin (5mg/kg, i.p.). Groups 3 to 5 received crocin (100, 200 and 400 mg/kg, i.p., respectively, for 4 consecutive days one hour before a single dose of cisplatin (5 mg/kg) only at the first day. Blood samples were taken out (on the fifth day) for measuring the level of urea and creatinine. The kidneys were removed for histopathological and biochemical examinations. Furthermore, 24-hour urinary factors were measured. **Results.** Blood urea, creatinine and urinary glucose and protein concentrations in crocin-treated groups were significantly lower than those of cisplatin-treated group in a dose-dependent manner. Histopathological studies showed a massive damage in S<sub>3</sub> segment of proximal tubules in cisplatin-treated group. No damage was observed in crocin-treated groups. Crocin treatment resulted in a significant and dose-dependent reduction in malondialdehyde concentration as compared to the cisplatin-treated group. Moreover, crocin produced a significant elevation in total thiol and glutathione peroxidase concentrations, as compared with cisplatin-treated group. **Conclusion.** The results of the present study suggest that crocin has a protective effect against cisplatin-induced acute renal failure and relative oxidative stress. *Iran. Biomed. J. 12 (2): 93-100, 2008*

**Keywords:** Acute renal failure, Oxidative stress, Cisplatin, Crocin, Renal protection

## INTRODUCTION

Cisplatin (*cis*-diamminedichloroplatinum II) is a chemotherapeutic agent, used in treatment of a variety of solid tumors, including ovary, testis, bladder, head and neck, lung, cervix, and endometrium. Anti-cancer activity of cisplatin is attributed to the conversion to a di-ucl-acquo complex, which forms an interstrand cross-link with double-strand DNA to prevent DNA synthesis. The most common adverse effect limiting the efficacy of this drug is nephrotoxicity which develops primarily in the S<sub>3</sub> segment of the proximal tubule. Although the exact mechanism of cisplatin-induced nephrotoxicity is not well understood, but according

to the previous results, some mechanisms are involved such as: depletion of sulfhydryl (SH) groups, impaired anti-oxidant defense system and mitochondrial dysfunction by inhibition of complexes I to IV of the respiratory chain in proximal tubules [1].

Several investigators also have shown that the reactive oxygen species (ROS) are closely related to the acute renal failure induced by cisplatin. In particular, the hydroxyl radical is highly reactive among oxygen radicals. Once excessive hydroxyl radicals are released, lipid peroxidation, produced by changes in the fluidity and permeability of membranes, is induced [2].

Acute renal failure, caused by cisplatin, is

\*Corresponding Author; Tel. (+98-915) 513 7443; Fax: (+98-611) 333 0074; E-mail: dr\_baharehnaghizadeh@yahoo.com

typically characterized by signs such as non-oliguria, severe reduction in glomerular filtration rate, variable fall in renal blood flow, decrease in the urinary concentrating ability and changes in urine volume, creatinine clearance and glutathione (GSH) status [3, 4].

Several anti-oxidants such as lipoic acid and thymoquinone have been tested for their ability to protect kidney against cisplatin-induced nephrotoxicity in experimental animals but the mechanisms of protective effects of these anti-oxidants are not fully known [5].

*Crocus sativus L.*, commonly known as saffron, is used in folk medicine as an anti-spasmodic, eupeptic, gingival, sedative, anti-catarrhal, carminative, diaphoretic, expectorant, stimulant, stomachic, aphrodisiac and emmenagogue [6]. In particular, modern pharmacological studies have demonstrated that saffron extract has anti-microbial [7], anti-convulsant [8], anti-depressant [9], anti-inflammatory [10], anti-tumour [11], radical scavenger [12], chemopreventive [13] as well as learning and memory improving properties [10] and promote the diffusion of oxygen in different tissues [12]. Saffron showed protective effects on genotoxins-induced oxidative stress in Swiss Albino mice [14]. Also, it has protective effect on cisplatin-induced nephrotoxicity in rat [15].

Crocin, one of the active components of saffron, is a carotenoid pigment and has the structure of crocetin di-gentiobiose ester [16]. Crocin exhibits a variety of pharmacological effects in mice including inhibition of skin tumour growth [17], improvement of learning behavior previously impaired by ethanol [18], prevention of long-term potentiation inhibition caused by ethanol in rat [18], anti-hyperlipidemic effect [19], treatment of colon adenocarcinoma in rat [20], anti-atherosclerotic effect [21] and anti-oxidant effect in PC-12 cells by increasing GSH synthesis [16,22].

The aim of the present study is to assess the protective effects of crocin against cisplatin-induced acute renal failure and oxidative stress in rat.

## MATERIALS AND METHODS

**Animals.** Adult male Wistar Albino rats weighing 180-200 g were used throughout the study. All animals were obtained from the Animal House of Mashhad Medical School (Mashhad, Iran). Animals were put separately in metabolic cages in an air-conditioned unit and were allowed free access to

food and tap water, ad libitum. A 12-h light/dark cycle at  $22 \pm 2^\circ\text{C}$  and 50% humidity conditions was maintained. All animal experiments were carried out in accordance with Mashhad University of Medical Sciences (Mashhad, Iran), Ethical Committee Acts.

**Chemicals.** Cisplatin was purchased from Ebeve Pharma (Austria). DTNB (5, 5'-dithiobis-2-nitrobenzoic acid) was obtained from Sigma (England). 2-thiobarbituric acid, n-butanol, Tris HCl,  $\text{Na}_2\text{EDTA}$ , phosphoric acid, potassium chloride, tetramethoxypropane, were obtained from Merck (Germany). Crocin was purchased from Fluka (Japan). GSH peroxidase kit was purchased from Randox Company (England). Urea kit was obtained from Man Lab Company (Tehran, Iran).

**Experimental design.** Animals were randomly divided into five groups (6 each) and individually put in metabolic cages. Group one received normal saline (2 ml/day) for four consecutive days as control group. Group two received a single dose of cisplatin (5 mg/kg) only at the first day of experiment. Groups three to five received crocin (100, 200 and 400 mg/kg, respectively), for four consecutive days followed by a single dose of cisplatin (5 mg/kg) only at first day. All injections were carried out intraperitoneally. At the fifth day, all animals were anaesthetized with ether; blood samples were taken out by cardiac puncture for measuring the level of urea and creatinine. The right kidney was immediately removed and fixed in 10% neutral buffered formalin for histopathological examination. The left kidney was removed, homogenized in cold KCl solution (1.5%) to give a 10% homogenate and used for measuring malondialdehyde (MDA), total thiol and GSH peroxidase concentrations. In addition, at the fourth day of experiment, 24-hour urine samples were collected for measuring glucose and protein concentration.

**Determination of blood urea and creatinine.** Urea concentration was measured colorimetrically by using Autoanalyzer and urea kit. Creatinine concentration was determined by Jaffe's method [23].

**Determination of urine glucose and protein.** Glucose concentration was estimated by the enzymatic assay (glucose oxidase) and protein concentration was measured by turbidimetric method [24, 25].

**Histopathological examinations.** The right kidney fixed in 10% formalin solution, then dehydrated in graded concentrations of alcohols, embedded in paraffin. Sections of 5µm were prepared and stained with hematoxylin and eosin (H&E). Light microscopy (Olympus PX 50 F3 model, Japan) was used to evaluate the kidney tissue.

**Thiobarbituric acid reactive species measurement.** MDA levels, an index of lipid peroxidation, produced with free radicals were measured. MDA reacts with thiobarbituric acid as a thiobarbituric acid reactive substance to produce a red colored complex that has peak absorbance at 532 nm. Briefly, 3 ml phosphoric acid (1%) and 1 ml TBA (0.6%) was added to 0.5ml of homogenate in a centrifuge tube and the mixture was heated for 45 min in a boiling water bath. After cooling, 4 ml n-butanol was added to the mixture and vortex-mixed for 1 min followed by centrifugation at 2000 rpm for 20 min. The colored layer was transferred to a fresh tube and its absorbance was measured at 532 nm. The standard curve of MDA was constructed over the concentration range of 0-20 µM [26].

**Total thiol (-SH) groups assay.** Total -SH groups were measured using DTNB (5, 5'-dithiobis- 2-nitrobenzoic acid) as the reagent [27]. This reagent reacts with the SH groups to produce a yellow colored complex which has a peak absorbance at 412 nm. Briefly, 1 ml Tris-EDTA buffer (pH 8.6) was added to 50 µl kidney homogenate in 2 ml cuvettes and absorbance was read at 412 nm against Tris-EDTA buffer alone ( $A_1$ ). Then, 20 µl DTNB reagents (10 mM in methanol) was added to the mixture and after 15min (stored in laboratory temperature), the sample absorbance was read again ( $A_2$ ). The absorbance of DTNB reagent was also read as a blank (B). Total thiol concentration (mM) was calculated from the following equation:

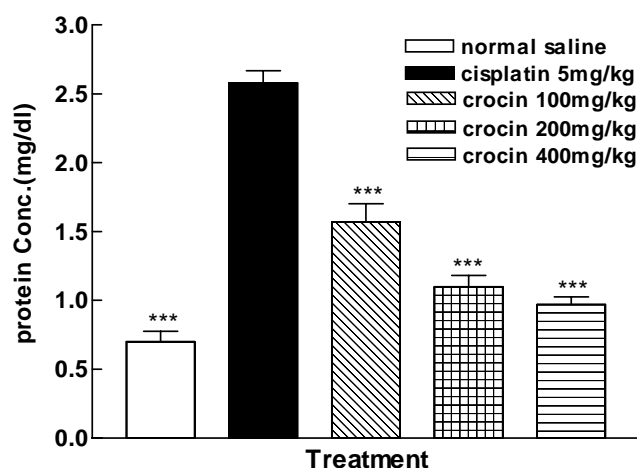
$$\text{Total thiol concentration (mM)} = (A_2 - A_1 - B) \times 1.07 / 0.05 \times 13.6$$

**Determination of GSH peroxidase concentration.** GSH peroxidase concentration was measured with the GSH peroxidase kit (Randox Company, England).

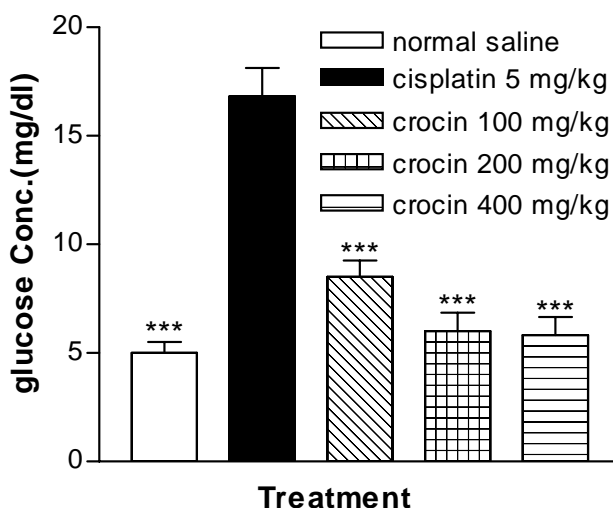
**Statistical analysis.** The values were presented as means  $\pm$  SEM. Differences between group means were estimated using a one-way ANOVA followed by Dunnet's test. Results were considered statistically significant when  $P < 0.05$ .

## RESULTS

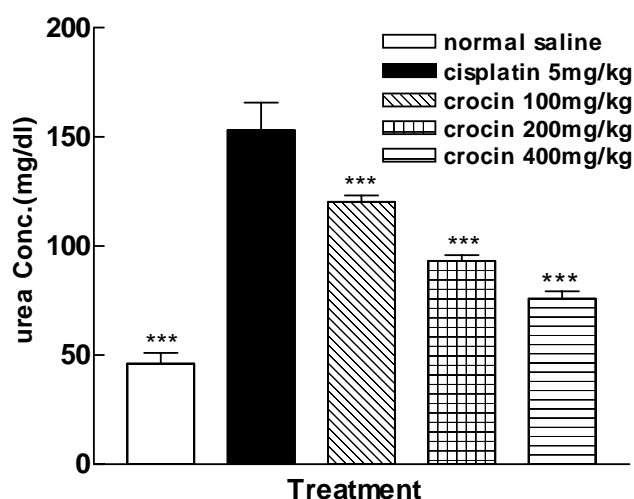
**Effects of cisplatin and crocin treatment on urine protein and glucose.** As shown in Figures 1 and 2, a marked increase in levels of protein and glucose was observed at the fifth day after cisplatin administration than that of corresponding controls ( $P < 0.001$ ). Crocin treatment resulted in a significant ( $P < 0.001$ ) and dose dependently reduction in the urine protein and glucose levels, compared to the cisplatin-treated group.



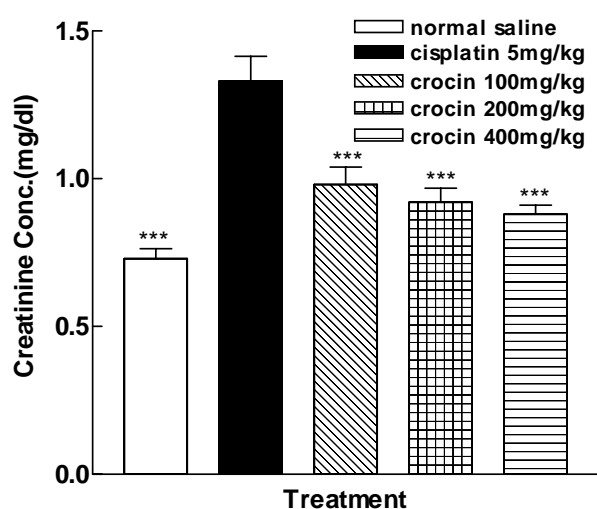
**Fig. 1.** Concentration of urinary protein in different treated groups. Data was shown as mean  $\pm$  S.E.M. \*\*\* $P < 0.001$  as compared with cisplatin-treated group ( $n = 6$ ).



**Fig. 2.** Concentration of urinary glucose in different treated groups. Data was shown as mean  $\pm$  S.E.M. \*\*\* $P < 0.001$  as compared with cisplatin-treated group ( $n = 6$ ).



**Fig. 3.** Concentration of blood urea in different treated groups. Data was shown as mean  $\pm$  S.E.M. \*\*\* $P$ <0.001 as compared with cisplatin-treated group ( $n$  = 6).

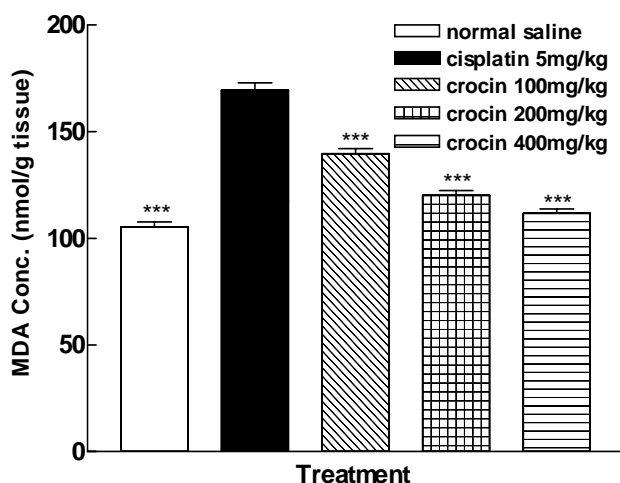


**Fig. 4.** Concentration of creatinine in different treated groups. Data was shown as mean  $\pm$  S.E.M. \*\*\* $P$ <0.001 as compared with cisplatin-treated group ( $n$  = 6).

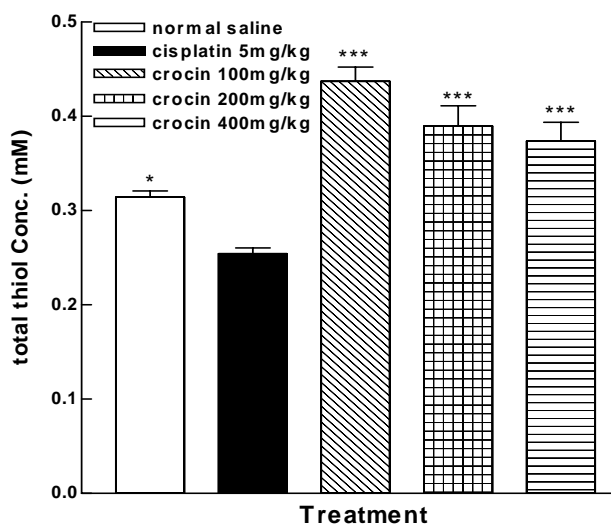
**Effects of cisplatin and crocin treatment on plasma creatinine and urea concentrations.** According to Figures 3 and 4, plasma urea and creatinine levels were significantly ( $P$ <0.001) higher in cisplatin-treated group than the controls. Crocin produced a significant ( $P$ <0.001) and dose dependently reduction in the urea and creatinine concentrations when compared to the cisplatin-treated group.

**Effects of cisplatin and crocin treatment on kidney MDA, total thiol and GSH peroxidase concentrations.** As shown in Figure 5, kidney MDA concentration was significantly higher in

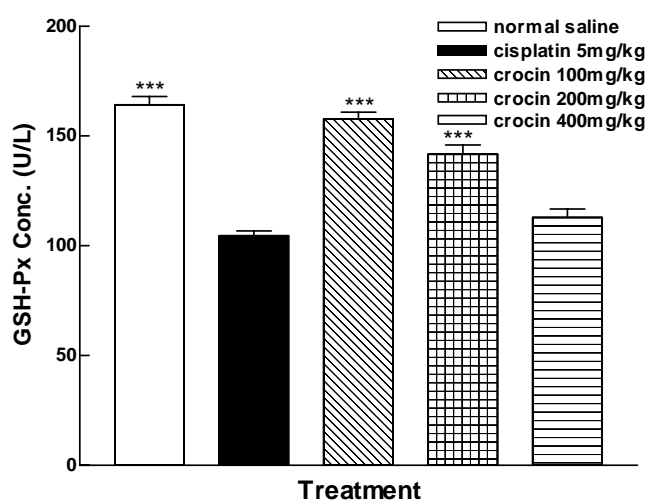
cisplatin-treated group when compared to the control group ( $P$ <0.001). Crocin treatment resulted in a significant ( $P$ <0.001) and dose dependently reduction in MDA concentration as compared to the cisplatin-treated group. In Figure 6, a significant reduction in total thiol groups in kidney homogenate samples was observed in cisplatin-treated group when compared to the control group ( $P$ <0.05). Crocin treatment caused a significant elevation in the total thiol concentration, as compared with cisplatin-treated group ( $P$ <0.001). At the dose of 100 mg/kg, crocin caused the best results and increased the total thiol groups over than that of the control group ( $P$ <0.001). According to Figure 7, cisplatin



**Fig. 5.** Concentration of MDA in different treated groups. Data was shown as mean  $\pm$  S.E.M. \*\*\* $P$ <0.001 as compared with cisplatin-treated group ( $n$  = 6).



**Fig. 6.** Concentration of total thiol in different treated groups. Data was shown as mean  $\pm$  S.E.M. \* $P$ <0.05 and \*\*\* $P$ <0.001 as compared with cisplatin-treated group ( $n$  = 6).



**Fig. 7.** Concentration of GSH peroxidase in different treated groups. Data was shown as mean  $\pm$  S.E.M. \*\*\* $P<0.001$  as compared with cisplatin-treated group (n = 6).


caused a significant reduction in the kidney GSH peroxidase level when compared to the control group ( $P<0.001$ ). Crocin treatment significantly increased GSH peroxidase concentration, as compared with cisplatin-treated group in 100 and 200 mg/kg doses ( $P<0.001$ ).

**Effects of cisplatin and crocin treatment on kidney histology.** All parts of kidney showed normal appearance in normal saline-treated group (Fig. 8A). Treatment with cisplatin caused a marked necrosis in the S<sub>3</sub> segment of the proximal tubule (CM junction), parenchyma degeneration of the tubular epithelial cells and interstitial nephritis (Fig. 8B). Treatment with crocin decreased the cisplatin-induced tubular necrosis (Fig. 8C).

## DISCUSSION

The present study indicated that crocin dramatically protected the cisplatin-induced *in vivo* nephrotoxicity in rat. However, the mechanisms underlying the cisplatin-induced acute renal failure have not been fully understood, several investigators have shown that the ROS or free radicals are closely related to the acute renal failure induced by cisplatin [32].

Several studies have reported that the alterations induced by cisplatin in the kidney functions were characterized by signs of injury, such as increase in products of lipid peroxidation and changes in total thiol concentration in kidney tissue as well as



**Fig. 8.** Light microscopy of renal tissue stained with H and E in different treated groups. (A) Normal saline, renal tubules, showed normal appearance; (B) Cisplatin, tubules, showed severe necrosis in CM junction; (C) Crocin and cisplatin, crocin, could protect kidney against cisplatin-induced necrosis. g, glomerul; d, distal tubule; p, proximal tubule, CM, corticomedullary junction (S<sub>3</sub>).

glucose, protein, creatinine and urea levels, in urine and plasma samples [4].

In the present study, it has been shown that administration of cisplatin to rat caused an elevation in urine glucose and protein levels, which correlated with increase in plasma creatinine and urea levels.

Also, cisplatin-induced nephrotoxicity was accompanied by an increase in MDA, reduction of total thiol and GSH peroxidase concentrations in kidney tissue. These biochemical parameters were well correlated with the renal histopathological results.

The current study demonstrates that crocin provides protection against cisplatin-induced acute renal failure in rat. Treatment with crocin resulted in a lower level of creatinine and urea in plasma and urinary levels of glucose and protein than cisplatin-received group, indicating improvement in the renal function. The histopathological evaluation of the kidney preparations in crocin-treated groups also revealed a decrease in cisplatin-induced tubular necrosis. Although the exact mechanism of cisplatin-induced nephrotoxicity is not well understood, several investigators have shown that cisplatin nephrotoxicity is associated with lipid peroxidation in renal tissue [4]. It has been suggested that binding of cisplatin to the renal base transport system and the following peroxidation of membrane lipids may account for its nephrotoxicity. There is evidence suggesting that cisplatin exerts its nephrotoxic effects by the generation of free radicals [1].

In the present investigation, treatment with crocin inhibited the increase in lipid peroxidation induced by cisplatin in renal tissue which was measured in terms of MDA, a stable metabolite of the free radical mediated lipid peroxidation cascade. MDA level was increased significantly in cisplatin-treated group. Crocin has reversed the enhancement of MDA level to a considerable extent, thereby confirming its anti-oxidant role in cisplatin acute renal failure [6].

GSH may modulate metal reduction and the thiol portion is very reactive with several compounds, mainly with alkylating agents such as cisplatin. One of the most important intracellular anti-oxidant systems is the GSH redox cycle. GSH is one of the essential compounds for maintaining cell integrity because of its reducing properties and participation in the cell metabolism. The depletion in the renal GSH level has been observed in rats in response to oxidative stress caused by cisplatin [28]. However, in this study, thiol (SH) groups are known to be sensitive to oxidative damage and were depleted following cisplatin administration. In our studies, total thiol groups were decreased following cisplatin administration. Crocin treated rats exhibited higher SH contents than cisplatin-treated group indicating that crocin helped in replenishing the total thiol pool.

The effect of crocin on total thiol concentration may be due to a direct anti-oxidant effect [22] and

enhanced biosynthesis of GSH [16] in agreement with the previous studies that indicate the effects of some anti-oxidants on cellular GSH may be due to directly anti-oxidant effects, enhanced biosynthesis of GSH or increase in levels of other anti-oxidants such as Vitamins A, and E [29, 30]. It has been suggested that cisplatin is able to generate ROS, and that is also inhibits the activity of anti-oxidant enzymes in renal tissue such as GSH peroxidase (Px) [4].

In this study, decreased concentration of GSH-Px was found in the kidney of rats treated by cisplatin. The selenium containing enzyme GSH-Px, protects cells against reactive oxygen substances via scavenging hydroperoxides and lipid peroxides. It is clear from this study that, crocin increased the GSH-Px concentration compared to cisplatin-received group. Carotenoids are well known as highly efficient scavengers of oxygen radicals and other excited species [31]. Thus, crocin may protect *in vivo* against oxidation of lipids, proteins and DNA. According to the different effects of crocin, it seems that more than one mechanism of protection is involved.

In conclusion, crocin is able to protect the kidneys against cisplatin-induced acute renal failure. But, before a conclusive statement on potential usefulness of crocin as adjunct to the cisplatin therapy, there is a need for further studies including human trials.

## ACKNOWLEDGEMENTS

The authors are thankful to the Vice Chancellor of Research, Mashhad University of Medical Sciences (Mashhad, Iran) for financial support.

## REFERENCES

1. Baek, S.M., Kwon, C.H., Kim, J.H., Woo, J.S., Jung, J.S. and Kim, Y.K. (2003) Differential roles of hydrogen peroxide and hydroxyl radical in cisplatin-induced cell death in renal proximal tubular epithelial cells. *J. Lab. Clin. Med.* 142: 178-186.
2. Satoh, M., Kashiwara, N., Fujimoto, S., Horike, H., Tokura, T., Namikoshi, T., Sasaki, T. and Makino, H. (2003) A novel free radical scavenger, Edarabone, protects against cisplatin-induced acute renal damage *in vitro* and *in vivo*. *J. Pharmacol. Exp. Ther.* 305: 1183-1190.
3. Kang, D.G., Lee, A.S., Mun, Y.J., Woo, W.H., Kim, Y.C., Sohn, E.J., Moon, M.K. and Lee, H.S. (2004)

- Butein ameliorates renal concentrating ability in cisplatin-induced acute renal failure in rats. *Biol. Pharm. Bull.* 27: 366-370.
4. Atessahin, A., Yilmaz, S., Karahan, I., Ceribasi, A.O. and Karaoglu, A. (2005) Effects of lycopene against cisplatin-induced nephrotoxicity and oxidative stress in rats. *Toxicology* 212: 116-123.
  5. Badary, O.A., Abdel-Maksoud, S., Ahmed, W.A. and Owieda, G.H. (2005) Naringenin attenuates cisplatin nephrotoxicity in rats. *Life. Sci.* 76: 2125-2135.
  6. Hosseinzadeh, H., Sadeghnia, H.R., Ziaee, T., Danaee, A. (2005) Protective effect of aqueous saffron extract (*Crocus sativus* L.) and crocin, its active constituent, on renal ischemia-reperfusion-induced oxidative damage in rats. *J. Pharm. Pharmaceut. Sci.* 8: 387-393.
  7. Vahidi, H., Kamalinejad, M. and Sedaghati, N. (2002) Antimicrobial properties of *Crocus sativus* L. *Iran. J. Pharmaceut. Res.* 1: 33-35.
  8. Hosseinzadeh, H. and Khosravan, V. (2002) Anticonvulsant effects of aqueous and ethanolic extracts of *Crocus sativus* L. stigmas in mice. *Arch. Iran. Med.* 5: 44-47.
  9. Hosseinzadeh, H., Karimi, G.H. and Niapoor, M. (2004) Antidepressant effects of *Crocus sativus* stigma extracts and its constituents, crocin and safranal, in mice. *ISHS Acta. Hort.* 650: 435-445.
  10. Hosseinzadeh, H. and Younesi, H.M. (2002) Antinociceptive and anti-inflammatory effects of *Crocus sativus* L. stigma and petal extracts in mice. *BMC Pharmacol.* 2: 1-8.
  11. Nair, S.C., Pannikar, B. and Panikkar, K.R. (1991) Antitumour activity of saffron (*Crocus sativus*). *Cancer Lett.* 57: 109-114.
  12. Rios, J.L., Recio, M.C., Ginger, R.M. and Manz, S. (1996) An update review of saffron and its active constituents. *Phytother. Res.* 10:189-193.
  13. Abdullaev, F.I. and Espinosa-Aguirre, J.J. (2004) Biomedical properties of saffron and its potential use in cancer therapy and chemoprevention trials. *Cancer Detect. Prev.* 28: 429-432.
  14. Premkumar, K., Abraham, S.K., Santhiya, S.T. and Ramesh, A. (2003) Protective effects of saffron (*Crocus sativus* L.) on genotoxins-induced oxidative stress in Swiss Albino mice. *Phytother. Res.* 17: 614-617.
  15. El-Daly, E.S. (1998) Protective effect of cysteine and vitamin E, *Crocus sativus* and *Nigella sativa* extracts on cisplatin-induced toxicity in rats. *J. Pharm. Belg.* 53: 87-95.
  16. Ochiai, T., Soeda, S.H., Ohno, S., Tanaka, H., Shoyama, Y. and Shimeno, H. (2004) Crocin prevents the death of PC-12 cells through sphingomyelinase-ceramide signaling by increasing glutathione synthesis. *Neurochem. Int.* 44: 321-330.
  17. Konoshima, T., Takasaki, M., Tokuda, H., Morimoto, S., Tanaka, H., Kawata, E., Xuan, L.J., Saito, H., Sugiura, M., Molnar, J. and Shoyama, Y. (1998) Crocin and crocetin derivatives inhibit skin tumour promotion in mice. *Phytother. Res.* 12: 400-404.
  18. Abe, K. and Saito, H. (2000) Effects of saffron extract and its constituent crocin on learning behavior and long-term potentiation. *Phytother. Res.* 14: 149-152.
  19. Lee, I.A.H., Lee, J.H., Baek, N.I. and Kim, D.H. (2005) Antihyperlipidemic effect of crocin isolated from the fructus of *Gardenia jasminoides* and its metabolite crocetin. *Biol. Pharm. Bull.* 28: 2106-2110.
  20. Garcia-Olmo, D.C., Riese, H.H., Escribano, J., Ontanon, J., Fernandez, J.A., Atienzar, M. and Garcia-Olmo, D. (1999) Effects of long-term treatment of colon adenocarcinoma with crocin, a carotenoid from saffron (*Crocus sativus* L.): an experimental study in the rat. *Nutr. Cancer* 35: 120-126.
  21. He, S.H.Y., Qian, Z.Y., Tang, F.T., Wen, N., Xu, G.L. and Sheng, L. (2005) Effects of crocin on experimental atherosclerosis in quails and its mechanisms. *Life. Sci.* 77: 907-921.
  22. Ochiai, T., Ohno, S., Soeda, S., Tanaka, H., Shoyama, Y. and Shimeno, H. (2004) Crocin prevents the death of rat pheochromyctoma (PC-12) cells by its antioxidant effects stronger than those of  $\alpha$ -tocopherol. *Neurosci. Lett.* 362: 61-64.
  23. Masson, P., Ohlsson, P. and Bjorkhem, I. (1981) Combined enzymic-jaff method for determination of creatinine in serum. *Clin. Chem.* 27: 18-21.
  24. Lott, J.A. and Turner, K. (1975) Evaluation of Trinder's glucose oxidase method for measuring glucose in serum and urine. *Clin. Chem.* 21: 1754-1760.
  25. McElderry, L.A., Tarbit, I.F. and Cassells-Smith, A.J. (1982) Six methods for urinary protein compared. *Clin. Chem.* 28: 356-360.
  26. Ohkawa, H., Ohishi, N. and Yagi, K. (1979) Assay for lipid peroxides in animal tissues by thiobarbituric acid reaction. *Anal. Biochem.* 95: 351-358.
  27. Sedlak, J. and Lindsay, R.H. (1968) Estimation of total, protein-bound, and nonprotein sulfhydryl groups in tissue with ellman's reagent. *Anal. Biochem.* 25: 192-205.
  28. Silva, C.R., Greggi Antunes, L.M. and Bianchi, M.D. (2001) Antioxidant action of bixin against cisplatin-induced chromosome aberrations and lipid peroxidation in rats. *Pharmacol. Res.* 43: 561-566.
  29. Kim, Y.K., Jung, J.S., Lee, S.H. and Kim, Y.W. (1997) Effects of antioxidants and  $\text{Ca}^{2+}$  in cisplatin-induced cell injury in rabbit renal cortical slices. *Toxicol. Appl. Pharmacol.* 146: 261-269.
  30. Tapiero, H., Townsend, D.M. and Tew, K.D. (2004) The role of carotenoids in the prevention of human pathologies. *Biomed. Pharmacother.* 58: 100-110.
  31. Stahl, W. and Sies, H. (2003) Antioxidant activity of carotenoids. *Mol. Aspects Med.* 24: 345-351.
  32. Sueishi, K., Mishima, K., Makino, K., Itoh, Y.,

- Tsuruya, K., Hirakata, H. and Oishi, R. (2002) Protection by a radical scavenger edaravone against cisplatin-induced nephrotoxicity in rats. *Eur. J. Pharmacol.* 451: 203-208.
33. Lin, J.K. and Wang, C.J. (1986) Protection of crocin dyes on the acute hepatic damage induced by aflatoxin B1 and dimethylnitrosamine in rats. *Carcinogenesis* 7: 595-599.