

Enterobius vermicularis in Cerebrospinal Fluid

Sharif Maraghi

Dept. of Mycoparasitology, School of Medicine, University of Medical Sciences, Ahwaz, Iran.

ABSTRACT

Enterobius vermicularis is a nematod of large intestine in man. Extra intestinal localization of this parasite is rare. A 60 year old man was admitted to the hospital with the clinical manifestation of meningitis. In laboratory examination of cerebrospinal fluid (C.S.F), the appearance was red, Albumin level was high and the glucose showed normal value. Haematoxylin and Eosin stained slides prepared from the precipitation revealed adults, larvae and ova of *Enterobius vermicularis*. This is the first report of *Enterobius vermicularis* in cerebrospinal fluid.

Keywords: Cerebrospinal fluid, *Enterobius vermicularis*

INTRODUCTION

Enterobius vermicularis is the most common intestinal parasite of man with the widest geographical distribution specially in the primary care setting, regardless of race, socioeconomic or culture circumstances [1]. Over 200 million persons are infected in the world. The male pinworm is about 2-5 mm in length and the female reaches a length of 8 to 13 mm. Upon ingestion of embryonated egg, first stage larva hatches in the duodenum. The liberated rhabditiform larva moult twice before reaching adolescence in the jejunum and upper ileum [2]. The adult worms inhabit the cecum and adjacent portion of the large and small intestine. The female worms, when fully gravid, migrate down the intestinal tract to pass out the anus and deposit their eggs. The clinical symptoms are due largely to the perianal. Perianal and vaginal irritation caused by the migration of the gravid female worm. Attachment of the adult worms to the intestine wall may produce some inflammation [3]. Signs and symptoms to the presence of pinworm in children are poor appetite, loss of sleep, weight loss, hyperactivity, enuresis, insomnia, irritability, grinding of the teeth, abdominal pain and vomiting [2].

CASE REPORT

A 60 year old man was admitted to Golestan hospital at Ahwaz city with the clinical manifestations of meningitis. In laboratory examination of C.S.F, the appearance was red, Albumin level was

high and the glucose showed normal value, Haematoxylin and Eosin stained slides prepared from the precipitation of centrifuged C.S.F revealed adult worm (Fig. 1a) larva (Fig. 1b) and ova (Fig. 1c) of *Enterobius vermicularis*. No bacteria growth in culture of C.S.F. Unfortunately the patient died.

DISCUSSION

Although the natural habit of *Enterobius vermicularis* is in large intestine, but many cases of ectopic enterobiosis have been reported. Invasion of appendicitis may be expected to be the common occurrence, which it is, but may relationship between this invasion and appendicitis remain unproved [4-7]. Invasion of the peritoneal cavity via the female reproductive system may result in the formation of abscess or granuloma around eggs or worms [8-10]. These are rarely of clinical significance but have been thought to be responsible for a chronic pelvic peritonitis [11]. Abscess of perianal was reported by Corea [12] and extra-intestinal pinworm abscess associated with hernia by Tomieporth *et al.* [13]. Adult worms of *Enterobius vermicularis* or ova have been seen in vaginal smears [14-16], in urine [17] and even in macerated human embryo [18]. Cases of dysuria, nocturia, enuresis [19], epididymitis [20], central haemorrhagic chorioretinopathy of the left eye [21], due to *Enterobius vermicularis* have been reported. Granuloma formation around pinworm eggs in the liver was reported by Little *et al* [22-24]. An adult female pinworm found on thoracotomy for

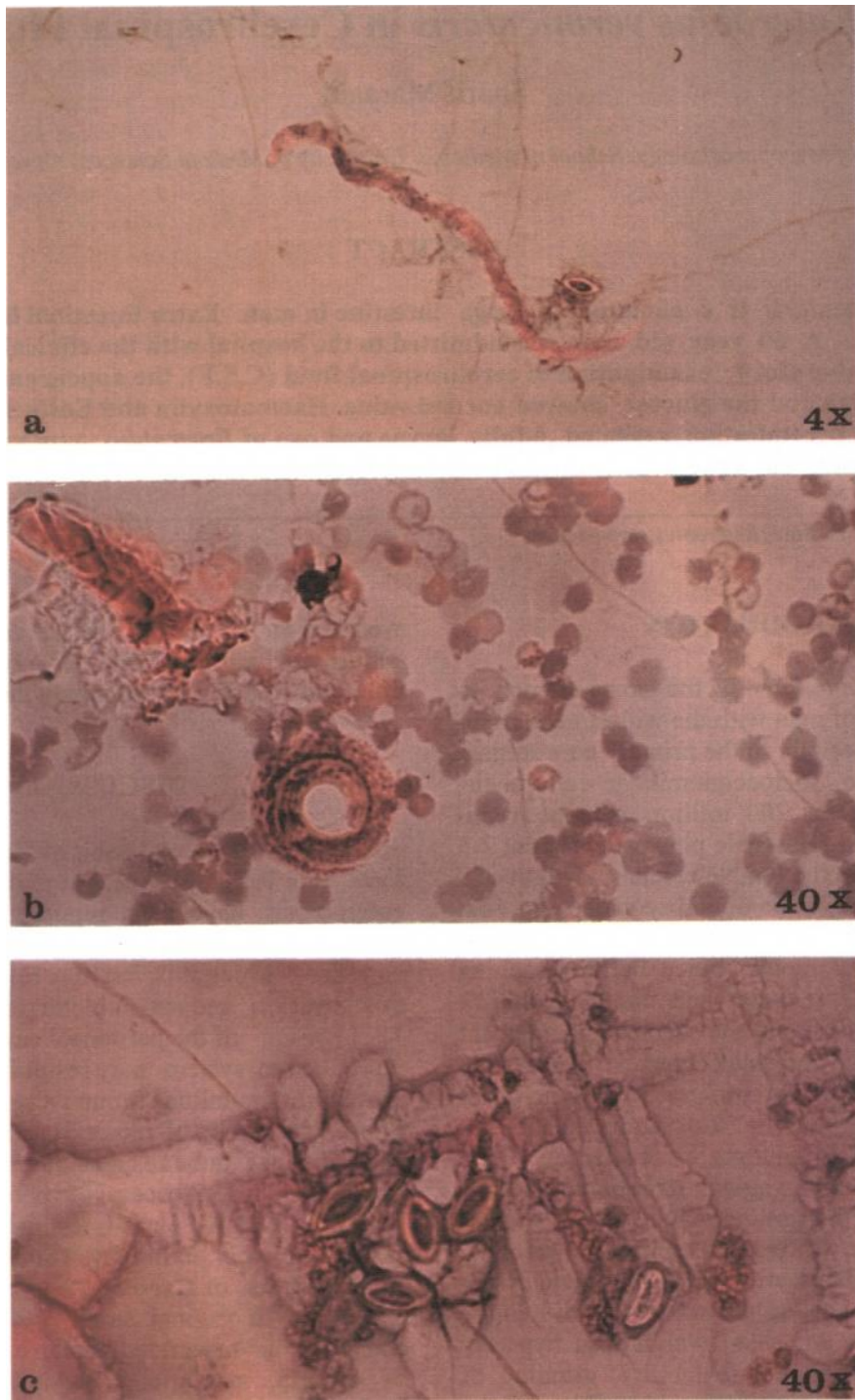


Fig. 1. Haematoxylin and Eosin stained C.S.F. precipitation. Note the adult worm (a), larva (b) and ova (c) of *Enterobius vermicularis*.

a non-calcified pulmonary nodule [25] is thought to have gained access to the peritoneal cavity via a necrotic area in an adenocarcinoma of the bowel. Chandrasoma and Mendis [26] present evidence that pinworms are able to penetrate actively through the intact bowel wall.

The present case is the first report of cerebrospinal enterobiasis and it is clear that *Enterobius vermicularis* can localize as an ectopic parasite in different sites of the body even in cerebrospinal fluid and cause pathological symptoms, but the question that how pinworm can gain access to C.S.F is remained to be answered.

REFERENCES

1. Russell, L.J. (1991) The pinworm, *Enterobius vermicularis*. Prim. Care. 18: 13-24.
2. Brown, H.W. and Neva, F.A. (1987) Basic clinical parasitology. 5th ed. Appleton century-crofts. New York PP. 128-132.
3. Markell, E.K., Voge, M., and John, D.T. (1986) Medical parasitology 6th ed. Saunders Company. London. PP. 220-222.
4. Bredesen, J., Falensteen, L.A., Kristiansen, V.B., Sorensen, C., and Kjersgard, P. (1988) Appendicitis and enterobiasis in children. Acta. Chir. Scand. 154: 585-587.
5. Babekir, A.R., and Devi, N. (1990) Analysis of the pathology of 405 appendices. East Afr. Med. J. 67: 599-602.
6. Wiebe, B.M. (1991) Appendicitis and *Enterobius vermicularis*. Scand. J. Gastroenterol. 26: 338.
7. Al Rabiah, F., Halim, M.A., Ellis, M.E., and Abdulkareem, A. (1996) *Enterobius vermicularis* and acute appendicitis. Saudi Med. J. 17: 799-882.
8. Mattia, A.R. (1992) Perianal mass and recurrent cellulitis due to *Enterobius vermicularis*. Am. J. Trop. Med. Hyg. 47: 811-815.
9. Mortensen, N.J., and Thomson, J.P. (1984) Perianal abscess due to *Enterobius vermicularis*. Report of 3 cases. Dis. Colon Rectum. 27: 677-678.
10. Vafai, M., Mohit, P. (1983) Granuloma of the anal canal due to *Enterobius vermicularis*, Report of a case. Dis. Colon. rectum. 26: 349-350.
11. Pearson, R.D., Irons, R.P Sr., and Irons, R.P Ir. (1981) Chronic pelvic peritonitis due to pinworm *Enterobius vermicularis*. J. Am. Med. Assoc. 245: 1340-1341.
12. Corea. R.T. (1983) *Enterobius vermicularis* in an ectopic site perianal abscess. Ceylon. Med. J. 28: 255-256.
13. Tomieporth, N.G., Disko, P., Brandis, A., and Barutzki, D. (1992) Ectopic enterobiasis. A case report and review. J. Infect. 24: 87-90.
14. Demirezen, S., Karayazgan, Y. (1986) Eggs of *Enterobius vermicularis*. in vaginal smears. Microbial. Bul. 20: 290-294.
15. Mckay, T. (1989) *Enterobius vermicularis* infection causing endometritis and persistent vaginal discharge in three siblings. N. Z. Med. J. 102: 56.
16. Deshpande, A.D. (1992) *Enterobius vermicularis* live adult worms in the high vagina. Postgrad. Med. J. 68: 690-691.
17. Adungo, N.I., Ondijo, S.O., and Pamba, H.O. (1989) Observation of *Enterobius vermicularis* ova in urine. 3 case reports. East. Afr. Med. J. 63: 676-678.
18. Mendoza, B., Jorda, M., Rafel, E., Simon, A., and Andrada, E. (1987) Invasion of human embryo by *Enterobius vermicularis*. Arch. Pathol-Lab. Med 111: 761-762.
19. Gokalp, A., Gultkin, E.Y., Kirisci, M.F., and Ozdamar, S. (1991) Relation between *Enterobius vermicularis* infestation and dysuria, nocturia, enuresis. Nocturia and bacteriuria in primary school girl. Indian pediater. 28: 948-50.
20. Kollias, G., Kyriakopoulos, M., and Tiniakos, G. (1992) Epididymitis from *Enterobius vermicularis*. case report. J. Urol. 147: 1114-1116.
21. Schmidt, D., and Cony, T. (1990) A case from practice. Eosinophilia in *Enterobius vermicularis* infection. Central haemorrhagic chorioretino-pathy of the left eye. Schewiz. Rundsch. Med. Prax. 79: 1308-1310.
22. Little, M.D., Cuello, C.J., and D'Alessandro, A. (1973) Granuloma of the liver due to *Enterobius vermicularis*. Am. J. Trop. Med. Hyg. 22: 567-569.
23. Daly, J.J., and Baker, G.F. (1984) Pinworm granuloma of the liver. Am. J. Trop. Med. Hyg. 33: 62-64.
24. Mondou, E.N., and Gnepp, D.R. (1989) Hepatic granuloma resulting from *Enterobius vermicularis*. Am. J. din. Pathol. 91: 97-100.
25. Beaver, P.C., Kriz, J.J., and Lau, T.J. (1973) Pulmonary nodule caused by *Enterobius vermicularis*. Am. J. Trop. Med. Hyg. 22: 711-713.
26. Chandrasoma, P.T., Mendis, K.N. (1977) *Enterobius vermicularis* in ectopic sites. Am. J. Trop. Med. Hyg. 26: 644-649.