

Comparative Study of Bone Repair Using Porous Hydroxyapatite/ β -Tricalcium Phosphate and Xenograft Scaffold in Rabbits with Tibia Defect

Zohreh Bagher¹, Farzad Rajaei^{*1} and Mohammadali Shokrgozar²

¹Cellular and Molecular Research Centre, Qazvin University of Medical Sciences, Qazvin; ²National Cell Bank of Iran, Pasteur Institute of Iran, Tehran, Iran

Received 29 May 2011; revised 29 November 2011; accepted 3 December 2011

ABSTRACT

Background: Bone tissue engineering requires materials that are biocompatible, mechanically suited for bone function, integrated with the host skeleton, and support osteoinduction of the implanted cells for new bone formation. The aim of this study was to compare the osteogenic potential of xenograft with hydroxyapatite/ β -tricalcium phosphate (HA/ β -TCP) scaffold. **Methods:** New Zealand rabbits (n = 9) were divided into 3 groups. Osteoblast cells were originally isolated from rabbit iliac crest and cultured in DMEM/F12. After creating a critical-sized defect (2 × 3 cm) in rabbit tibia bone, the defect was filled with an implant of HA/TCP with osteoblasts and xenograft in the hole of left (as control) and right tibia, respectively. The new bone formation and the development of bone union within the defect were evaluated by x-ray images and eosine and hematoxylin staining at 4, 8, and 12 weeks post-operation. **Results:** The bone partially formed in both groups was filled with osteoblast cultured on porous implants at 4 weeks. Over time, progressive bone regeneration was observed inside the pores. Moreover, a progressive vascular ingrowth and progressive integration with the host bone were obvious in xenograft when compared to HA/ β -TCP. A good integration between the xenograft implants and the bone was observed radiographically and confirmed by histological section. **Conclusion:** The result showed that the bone defect can be repaired using both synthetic and xenograft implants. However, the xenograft showed a better osteointegration as compared to HA/ β -TCP scaffold. *Iran. Biomed. J. 16 (1): 18-24, 2012*

Keywords: Osteoblasts, Hydroxyapatite/ β -Tricalcium phosphate (TCP), Bone tissue

INTRODUCTION

The reconstruction of large bone segments remains a significant clinical problem in the case of extensive bone loss due to pathological events, such as trauma, inflammation, and surgical treatment of tumors. Bone substitutes appear to be the most demanded implantation materials in clinical approaches. Particularly, the current clinical treatments for critical-sized defects are often problematic and seem to be a serious challenge for orthopedic surgeons [1-3]. For this purpose, the application of autologous bone grafts can be a milestone due to its ability to regenerate bone defects. However, disadvantages such as limited availability of bone and the risk of infection have been advocated an alternative bone graft [4-7]. To overcome these problems, the tissue engineering has emerged with the aim of developing tissue and synthetic materials [8]. To date, the synthetic porous-bioceramic materials such as hydroxyapatite (HA) and

tricalcium phosphate (TCP) have been widely used as bone substitutes due to their ideal (desirable) biocompatibility, osteoconductive properties, and risk-free rejection or infection [9].

HA is a major calcium phosphate constituent of native bone, extensively proved for its osteoconductivity [10]. Tricalcium phosphate is also a biocompatible and biodegradable material with four polymorphs (α , α' , β , γ) [11]. Among different TCP polymorphs, the β -TCP is intensively investigated as a bioactive bone graft material [12]. It should be noticed that the degradation rate of the biopolymers is an important issue which must be considered for tissue engineering applications. To achieve this goal in the current study, the β -TCP in combination with HA was applied to enhance the degradability rate of HA. Application of the HA/ β -TCP blend system would combine the properties that are unique to each (such as superior structural properties and biodegradability) [13-16]. In addition to artificial bone substitutes, the

*Corresponding author. Cell phone: (+98-912) 2817421; E-mail: farzadraj@yahoo.co.uk

xenograft is also another candidate for bone reconstruction due to advantages, such as natural, porous, cancellous bone mineral derived from sheep. Additionally, Xenograft possibly contains inorganic substances such as Na and Mg apart from calcium phosphate while synthetic calcium phosphate does not have [17]. Therefore, it seems that the Xenograft to be an appropriate substitute as compared to artificial bone. Worth *et al.* [18] have shown that the processed bovine cancellous bone xenografts are osteoconductive with great promise for development as a biomaterial in human and orthopedic surgeries.

Hence, we assume that in an optimal condition, xenograft might be a feasible approach for the clinical reconstruction of segmental defect and could be more effective. In addition, it was shown that the transplantation of culture cell in combination with bone graft and calcium ceramics yields a good outcome in bone regeneration [9, 19]. This theory indicates that these cells would proliferate and secrete an osteoinductive matrix on the surfaces of the scaffold, which would facilitate the healing process even if the cells fail to survive implantation of the biomaterial [20]. Therefore, in the present study, we used autologous osteoblast cells, obtained from rabbit iliac crest, for seeding on both HA/ β -TCP and xenograft scaffolds. However, various commercial bone substitute materials of different origin, chemical composition, and micro- or macro-structural properties have been introduced so far and investigated in recent years [21-23]. A major issue for the clinical practitioners is whether a bone graft acts as a plain defect filler, or has additional capacities [24]. Our aim was to evaluate the therapeutic effects of HA/TCP, which is one of the most popular commercial clinical bone substitutes, and also to compare this product with xenograft, which has a similar structure and function to autologous bones.

MATERIALS AND METHODS

Isolation of osteoblast cells from iliac bone. To isolate the osteoblast cells from iliac bone, 9 adult rabbits with weights ranging from 1.5 to 1.7 kg were used. The animals were separated into 3 groups of equal weight and anesthetized with a combination of ketamine (60 mg/kg) and xylazine (6 mg/kg) (both from Sigma, USA), administered by intramuscular injection. An approximately 2 cm incision was made over the left iliac crest to the iliac bone which was well-exposed by removing soft tissue. Then, a part of the outer cortical layer was removed and a sufficient quantity of cancellous bone was obtained using a cutter. At first, the connective tissue and residual non-specific cells were removed from the trabecular bone, rinsed several

times in sterile (pH 7.4). The trabecular bone was transferred into a sterile Petri dish containing PBS and dissected into pieces of 2-3 mm in diameter. The bone fragments were then digested in a 2-mg/ml collagenase type II (Gibco, Scotland) in 5% CO₂ at 37°C for 20-30 minutes. Subsequently, the bone chips were seeded into a 50-cm² cell culture flask containing DMEM and Ham's F12 medium (both from Gibco, Scotland), supplemented with 10% fetal bovine serum, 100 IU/ml penicillin and 100 μ g/ml streptomycin (all from Sigma, USA) in 5% CO₂ at 37°C.

Cell culture. The osteoblast cells originally isolated from iliac bone were cultured in DMEM/F12 with 10% fetal bovine serum. After 3 days, the medium was replaced with an equal volume of fresh medium and the non-adherent cells were removed from the flask. The osteoblast cells migrated from the bone fragment into cell culture plates within 10-12 days. The obtained cells were grown in an atmosphere of 5% CO₂ with 85% relative humidity at 37°C while the primary culture media were changed every three days. After 10 days, the cell cultures were at 50% confluency. The cultures were then rinsed with PBS twice, scratched from the flask bottom with 2 ml trypsin/EDTA (Sigma, USA), concentrated by centrifugation at 270 \times g for 5 min, and diluted to 2×10^6 cells/ml in osteoblastic culture media to be seeded into the scaffolds.

Staining of mineralized matrix. von Kossa staining is a routine histological technique, which is used to demonstrate deposits of calcium or calcium salt and bone nodule formation in bone cell culture studies. Approximately 5×10^3 cells were seeded onto Petri dishes and fixed in 10% formaldehyde for 15-30 minutes. Afterward, they were rinsed in several changes of distilled water, incubated with 5% silver nitrate solution (Sigma, USA), placed under ultraviolet light for 30 minutes, and eventually washed in PBS. Finally, the osteoblast cells were fixed in 0.3% sodium thiosulfate (Sigma, USA) for 5 minutes, followed by observation of calcium deposition nodules by a light microscope (Zeiss, Germany).

Cell seeding on scaffolds. To make a primary attachment, a total of 5×10^5 cells/sample was seeded on the surfaces of composites under the minimum volume of the culture medium. The cell-scaffold complex was incubated in 5% CO₂ at 37°C for 4 hours. Afterward, 2 ml of medium was carefully added to each well, and the samples were re-incubated for 2 weeks before implantation. The old medium was replaced by fresh medium every three days and cell morphology on the scaffolds was visualized using a scanning electronic microscope.




Fig. 1. von Kossa staining of osteoblast cells. Calcium depositions are recognized as black nodules (original magnification $\times 400$).

Scanning electron microscopy. SEM illustration was performed as described for adhesion study [25]. Following harvesting the osteoblast cells on both scaffolds at 37°C for 5 days, the samples were fixed in 1.5% glutaraldehyde solution for 24 hours. The composites were dehydrated using a serial dilution of ethanol (10-100%). The samples were then sputter-coated before examining by a scanning electronic microscope (Zeiss, Germany) operated at voltage of 20 KV.

Preparation of xenograft. The sheep bones were used as a source for preparation of xenografts. The bones, collected from freshly killed animals, were immediately placed in a suitable sterile isotonic solution in an approximate range of 5-20°C to minimize the enzymatic degradation of the bone tissue. The bone material was broken into small blocks as big as the HA/ β -TCP blocks. Then, the graft was immersed in 70% ethanol at room temperature for about 5 minutes to sterilize the bone as well as to remove the residual blood proteins and non-collagenous materials. Freezing/thawing method was used to subject the xenograft to a cellular disruption. Preferably, the xenograft was dipped into liquid nitrogen for about 5 minutes, and then the xenograft was frozen at -20°C. Subsequently, the xenograft was thawed by immersion in an isotonic saline bath at room temperature for about 10 minutes. Finally, the xenograft was treated with galactosidase (Sigma, USA) for removal of surface carbohydrate moieties.

Surgical procedure. Rabbits were anesthetized as mentioned before. The hair over the medical aspect of both tibias was shaved and the skin was disinfected with Betadine. Using a drill, a hole was created and a longitudinal incision about 2 \times 3 cm in length was made over the medical aspect of both tibias. This was followed by implanting the HA/ β -TCP composites into the left hole while the right tibia received the xenograft

substitute. Three doses of gentamicin (10 mg) were administered to prevent post-operation infection.

Radiological and histological evaluation. Animals were sacrificed at 4th, 8th, and 12th weeks. After these time intervals, the antrolateral radiographs were taken from the specimens. The bone grafts were fixed in buffered 10% formaldehyde solution for 24 h. Fixed bone tissues were decalcified in 10% nitric acid for a period of 24-72 h followed by deacidification under tap water. After tissue processing, paraffin blocks were prepared and 5- μ m sections were made using a microtome. Afterward, the sections were stained with eosine and hematoxylin and examined under a light microscope.

RESULT

Calcium staining (von Kossa). Calcium deposition was recognized as black nodules as shown in Figure 1. After incubation intervals, the osteoblast cells produced bone nodules in all extraction solutions.

Evaluation of scanning electron microscope. SEM studies were performed on osteoblast cells attached to both samples prior to implantation. As seen in Figure 2, the cells have covered the surface of the samples while maintaining their normal morphology with obvious adherence and proliferation, demonstrated on the surface of the samples.

Four weeks post-operation assessment. Histological evidence of both grafts showed the defect was sealed with a thin layer of bone. The new bone was more restricted to the defect margins. Microscopic examination demonstrated that the new bone formation was mainly originated from the bony borders directed toward the center. However, the gap was filled with a small amount of new bone as seen in Figure 3A and 3B. X-ray image showed a radiolucent pattern, which was clearly seen in the interface between the native bone and grafts. No consistent difference was identified between both grafts (Fig. 4a).

Eight weeks post-operation assessment. Eight weeks after engraftment, extensive recruitment of woven bone structures was observed as compared to 4-week-old specimens; however, as seen in X-ray photographs, the bone formation within both scaffolds is not complete. In histological assay, a few activated osteoblast cells were observed around the bony margins of the xenograft defect. These osteoblast cells had the ability to partially synthesize the new bone tissue in areas next to the defects (Fig. 3C). As shown in Figure 3D, the penetration of blood vessels was also observed




Fig. 2. Scanning electron microscopy (SEM) of osteoblast prior to implantation. Osteoblasts with normal morphology are shown while adhered on the surface of xenograft (A) and HA/ β -TCP (B) scaffolds.

throughout the HA/ β -TCP grafts. A filling increase in bone deposition within the scaffold pores in addition to the scaffold destruction is more considerable in HA/ β -TCP compared to xenograft. In xenograft, a bony union was obvious, although no clear boundary between the newly formed bone and native bone constructions was observed. The xenograft scaffold integrated well with the host bone in tibia defects, was

demonstrated by new bone formation at the implant-host interfaces. X-ray findings further supported the histological evidence. Radiographically, the interface between the native bone and constructs was indistinct (Fig. 4b).

Twelve weeks post-operation assessment. The results of radiographic and histological evaluations

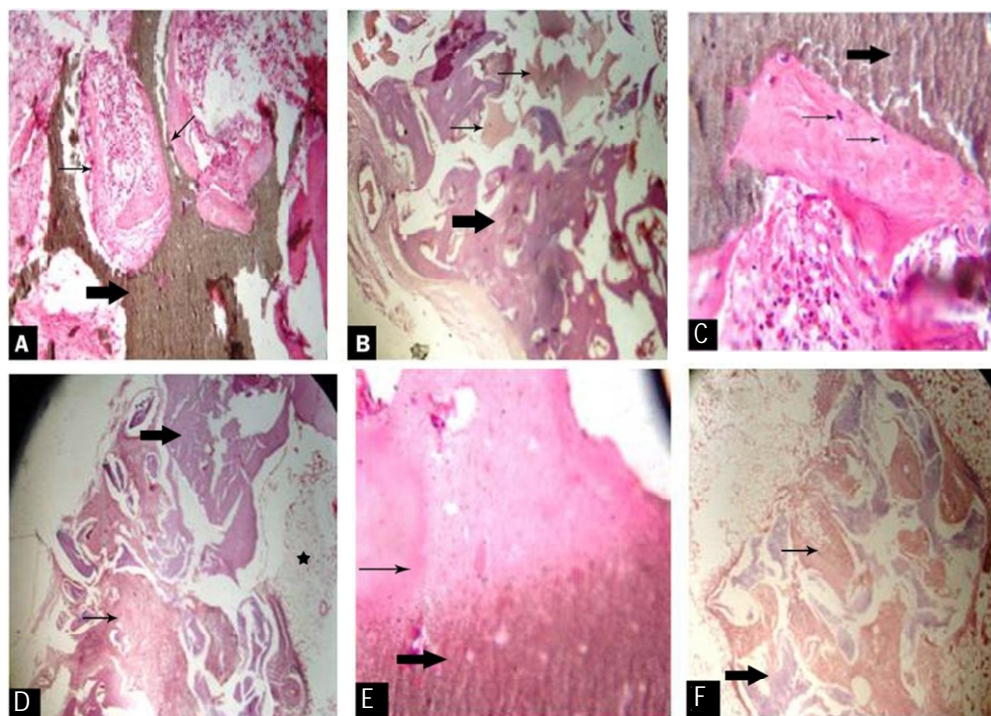


Fig. 3. Photomicrographs of HA/ β -TCP and Xenograft Scaffolds at 4, 8 and 12 weeks post surgery in rabbit tibia defect. Thin arrows indicate the new bone formation in all pictures and thick arrows indicate the xenograft in (A, C, E) and HA/ β -TCP in (B, D, F). Small vessels (★) observed in picture are penetrating into the formed bone tissues (eosine and hematoxylin staining, $\times 400$).

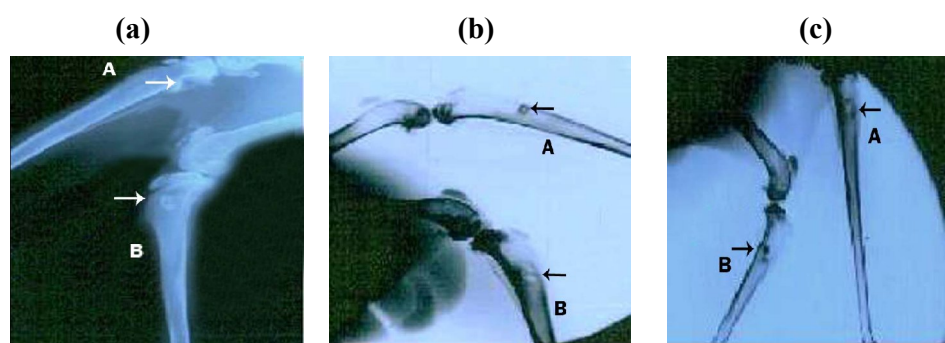


Fig. 4. X-ray photographs of HA/ β -TCP and Xenograft Scaffold at 4, 8 and 12 weeks post surgery. Arrows indicate the xenograft (A) and the HA/ β -TCP (B) in the defect sites. Good integration between the xenograft implants and the bone at 12 weeks post surgery (c) are shown as compared to the implants at 4 (a) and 8 weeks (b).

at 12 weeks post-operation showed that both grafted tibia were healed with fusion of the graft into the margin of the defect, while the reformation of more normal anatomy was clear. At 3 months, the macroscopic evaluation showed that the surface of the implants was as smooth as it was prior to implantation. The microscopic evaluation showed that the both of defects were completely filled with new bone formation after 12 weeks (Fig. 3E and 3F). This could be confirmed by the exposition of progressive appearance of cracks within the implants. This process indicated some scaffold disintegration, while bone formation was in progress yet this was more obvious in HA/ β -TCP scaffold (Fig. 3B). The defects reconstructed with cell-xenograft scaffolds appeared to be similar to the native bone as revealed by the level of radiopacity at the site of defect, indicative of good chemical bonds between the bone and implants. X-ray images obtained from the synthetic groups demonstrated that the scaffold was distinguishable at the margins from the native bone. The defects reconstructed with HA/ β -TCP appeared radiolucent in most part of the defect (Figs. 3 and 4c).

DISCUSSION

Large bone defects represent a major problem in regenerative medicine [25]. Currently, several different therapeutic approaches, such as transplant of autologous, allogeneic, and xenogeneic bone graft or the application of different biomaterial implants have been proposed, but so far, none have shown to be totally appropriate [26]. However, the demand for easy-to-apply implant material for repair of complex-shaped bone defect is on the rise. It has been reported that the culture of seeded osteoblastic cells in three-dimensional osteoconductive scaffolds *in vitro* is a promising approach to produce an osteoinductive

material to repair bone defects [20]. Also, it is claimed that the angiogenesis is essential for the delivery of oxygen and nutrients required for bone formation [9] and that the vascular endothelial growth factor is highly expressed by osteoblastic cells, indicating that the addition of osteoblastic cells also facilitate the growth of vessels into the scaffold [27]. For this similar reason, the osteoblasts were seeded into the scaffolds and the cell cultured scaffold was implanted into the defect of tibia.

In the current study, the performance of osteoblast cells seeded on HA/ β -TCP as bone substitute was investigated *in vivo* and the results were further compared with those of xenograft while the rate of osteogenesis was also evaluated at 4, 8, and 12 weeks after surgery. The bone partially formed in both groups was filled with osteoblast and cultured on porous implants at 4 weeks. Over the time, progressive bone regeneration was observed inside the pores (Fig. 3F). Moreover, progressive vascular ingrowth and integration with the host bone was observed in xenograft compared with HA/ β -TCP. Our findings are in accordance with those found by Keshina *et al.* [28] who demonstrated that the combination of xenograft with autologous bone marrow could accelerate their incorporation into the host bed. The structure of xenograft consists of wide and interconnecting pore system that enables this material to be served as a physical scaffold for osteogenic cells, thus promoting the migration and subsequent attachment of these cells [14]. Sicca *et al.* [29] reported that the xenograft composites promote the bone regeneration in a similar fashion to autogenous bone. Histological and radiological evaluation at 12 weeks post-operation showed definite evidence of bone formation and bridging between the proximal and distal edges of the defect in both groups but more significant was the well-integration of the xenograft scaffold with the host bone. Good integration between the xenograft implants

and the bone was observed radiographically and confirmed by histology. Therefore, it is reasonable to consider the xenograft as an organic material with bioaffinity to host animals rather than being recognized as a foreign substance and this may be of great clinical importance [30].

One of the disadvantages of xenografts cited by some authors is the risk of disease transmission, but it is known that an organic material such as that used in our experiments offers a lower risk in this regard than the fresh frozen tissue because of the procedure in which they are processed [31, 32]. Based on the data obtained from the present study, it is suggested that the xenografts to be utilized more widely in the future. Eventually, it has to be the goal of future controlled randomized clinical trials to exactly clarify the effectiveness and the cost/benefit superiority of the xenograft approach compared to other methods of bone reconstruction. Eventually, controlled randomized clinical trials will have to clarify the effectiveness and the cost/benefit superiority of the xenograft approach compared to other methods of bone reconstruction. Based on the data obtained from the present study, it is suggested that the xenografts to be utilized more widely in future.

This study indicates that the tibia defects can be successfully reconstructed by *in vitro* culture of autologous osteoblast with both HA/ β -TCP and xenograft scaffold. Although the scaffold material derived from sheep bones provides a feasible method to repair the critical segmental bone defects in rabbits, the autologous osteoblasts can enhance the efficacy of the technique. The main finding of this investigation is the better integration of xenograft scaffold with the host bone in tibia defects compared to HA/ β -TCP. Taken together, this study proposes a bone-derived scaffold and a cell source, possibly in large supply, to be used in large size bone defects.

ACKNOWLEDGMENTS

The authors express their gratitude to the Research Department of Qazvin University of Medical Sciences (Qazvin, Iran) for its financial support, and also the staffs of the Cell Bank Division of the Pasteur Institute of Iran for their cooperation.

REFERENCES

- Kim WS, Kim HK. Tissue engineered vascularized bone formation using *in vivo* implanted osteoblast-polyglycolic acid scaffold. *J Korean Med Sci*.2005 Jun;20(3):479- 82.
- Cancedda R, Giannoni P, Mastrogiacomio M. A tissue engineering approach to bone repair in large animal models and in clinical practice. *Biomaterials*.2007 Oct;28(29):4240-50.
- Khan SN, Cammisa Jr FP, Sandhu HS, Diwan AD, Girardi FP, Lane JM. The biology of bone grafting. *J Am Acad Orthop Surg*.2005 Jan-Feb;13(1):77-86.
- Cowan CM, Soo C, Ting K, Wu B. Evolving concepts in bone tissue engineering. *Curr Top Dev Biol*.2005;66:239-85.
- Vaccaro AR. The role of the osteoconductive scaffold in synthetic bone graft. *Orthopedics*.2002 May;25(5 Suppl):s571-8.
- Finkemeier CG. Current concepts review: bone-grafting and bone-graft substitutes. *J Bone Joint Surg*.2002 Mar;84:454-64.
- Mistry AS, Mikos AG. Tissue engineering strategies for bone regeneration. *Adv Biochem Eng Biotechnol*.2005;94:1-22.
- Service RF. Tissue engineers build new bone. *Science*. 2000 Sep;289(5484):1498-1500.
- Wu W, Chen X, Mao T, Chen F, Feng X. Bone marrow-derived osteoblasts seeded into porous beta-tricalcium phosphate to repair segmental defect in canine's mandibular. *Ulus Travma Acil Cerrahi Derg*.2006 Oct;12(4):268-76.
- LeGeros RZ. Properties of osteoconductive biomaterials: calcium phosphates. *Clin Orthop Relat Res*.2002 Feb;395:81-98.
- Welch JH, Gutt W. High-temperature studies of the system calcium oxide-phosphorous pentoxide. *J Chem Soc*.1961;4442-4.
- Ryu HS, Hong KS, Lee JK, Kim DG, Lee JH, Chang BS, Lee DH, et al. Magnesia-doped HA/b-TCP ceramics and evaluation of their Biocompatibility. *Biomaterials*. 2004;25:393-401.
- Yuan H, De Bruijn JD, Li Y, Feng J, Yang Z, De Groot K et al. Bone formation induced by calcium phosphate ceramics in soft tissue of dogs: a comparative study between porous alpha-TCP. *J Mater Sci Mater Med*. 2001 Jan;12(1):7-13.
- Ohura K, Böhner M, Hardouin P, Lemaître J, Pasquier G, Flautre B. Resorption of, and bone formation from, new beta-tricalcium phosphate-monocalcium phosphate cements: an *in vivo* study. *J Biomed Mater Res*. 1996 Feb; 30(2):193-200.
- Block JE, Thorn MR. Clinical indications of calcium-phosphate biomaterials and related composites for orthopedic procedures. *Calcif Tissue Int*.2000 Mar;66(3):234-8.
- Ohgushi H, Okumura M, Yoshikawa T, Inoue K, Senpuku N, Tamai S et al. Bone formation process in porous calcium carbonate and hydroxyapatite. *J Biomed Mater Res*.1992 Jul;26(7):885-95.
- Tapety FI, Amizuka N, Uoshima K, Nomura SH, Maeda T. A histological evaluation of the involvement of Bio-Oss in osteoblastic differentiation and matrix synthesis. *Clinic Oral Impl Res*.2004 Jun;15(3):315-24.
- Worth A, Mucalo M, Horne G, Bruce W, Burbidge H. The evaluation of processed cancellous bovine bone as a bone graft substitute. *Clin Oral Implants Res*.2005 Jun;16(3):379-86.

19. Orii H, Sotome SH, Chen J, Wang J, Shinomiya K. Beta-tricalcium phosphate (beta TCP) graft combined with bone marrow stromal cells (MSCs) for posterolateral spine fusion. *J Med Dent Sci.*2005 Mar;52(1):51-7.
20. Goldstein AS, Juarez TM, Helmke CD, Gustin MC, Mikos AG. Effect of convection on osteoblastic cell growth and function in biodegradable polymer foam scaffolds. *Biomaterials.*2001 Jun;22(11):1279-88.
21. Klein M, Goetz H, Pazen S, Al-Nawas B, Wagner W, Duschner H. Pore characteristics of bone substitute materials assessed by microcomputed tomography. *Clin Oral Implants.*2009 Jan;20(1):67-74.
22. Tadic D, Epple M. A thorough physicochemical characterization of 14 calcium phosphate-based bone substitution materials in comparison to natural bone. *Biomaterials.*2004 Mar;25(6):987-94.
23. Weibrich G, Tretin R, Gnoth SH, Götz H, Duschner H, Wagner W. Determining the size of the specific surface of bone substitutes with gas adsorption. *Mund Kiefer Gesichtschir.*2000 May;4(3):148-52.
24. Albrektsson T, Johansson C. Osteoinduction, osteoconduction and osseointegration. *Eur Spine J.*2001 Oct;10(suppl 2):96-101.
25. Shokrgozar MA, Farokhi M, Rajaei F, Bagheri MH, Azari Sh, Ghasemi I, Mottaghitalab F, et al. Biocompatibility evaluation of high purified human osteoblast cells on β -TCP nanoparticles reinforced HDPE-UHMWPE blend composites. *J Biomed Mater Res A.*2010;95(4):1074-83.
26. Meinel L, Fajardo R, Hofmann S, Langer R, Chen J, Snyder B et al. Silk implants for the healing of critical size bone defects. *Bone.*2005 Nov;37(5):688-98.
27. Marcacci M, Kon E, Moukhachev V, Lavroukov A, Kutevov S, Quarto R et al. Stem cells associated with macroporous bioceramics for long bone repair: 6- to 7-year outcome of a pilot clinical study. *Tissue Eng.*2007 May;13(5):947-55.
28. Tokuda H, Kato K, Oiso Y, Kozawa O. Contrasting effects of triiodothyronine on heat shock protein 27 induction and vascular endothelial growth factor synthesis stimulated by TGF-beta in osteoblasts. *Mol Cell Endocrinol.*2003 Mar;201(1-2):33-8.
29. Keskin D, Gündoğdub C, Atac AC. Experimental comparison of bovine-derived xenograft, xenograft-autologous bone marrow and autogenous bone graft for the treatment of bony defect in the rabbit ulna. *Med Princ Pract.*2007;16(4):299-305.
30. Sicca CM, Corotti MV, Sgarbosa SH, Cestari TM, Cavalcanti MG, Ferreira PM et al. JM. Comparative histomorphometric and tomographic analysis of maxillary sinus floor augmentation in rabbits using autografts and xenografts. *J Biomed Mater Res.*2008 Jul;86(1):188-96.
31. Calasans-Maia MD, Ascoli FO, Novellino ATN, Rossi AM, Granjeiro JM. Comparative histological evaluation of tibial bone repair in rabbits treated with xenografts. *Acta Ortop Bras.*2009;17(6):340-3.
32. Tapety FI, Amizuka N, Uoshima K, Nomura S, Maeda T. A histological evaluation of the involvement of Bio-Oss in osteoblastic differentiation and matrix synthesis. *Clin Oral Implants Res.*2004 Jun;15(3):315-24.