

Molecular Evidence on Changing Pattern of Mixed *Plasmodium falciparum* and *P. vivax* Infections during Year-Round Transmission of Malaria in Chahbahar, Iran

Sedigheh Zakeri^{1*}, Parin Naimi², Mohammad Zare³, Mehdi Zand Haghighi⁴ and Navid Dinparast-Djadid¹

¹Malaria Research Group (MRG), Dept. of Biotechnology, Pasteur Institute of Iran, Tehran; ²Khatam University, ³Malaria Control Program, Center for Diseases Prevention and Control, Tehran; ⁴Dept. of Public Health, Chahbahar, Sistan and Baluchistan province, Iran

Received 10 May 2003; revised 11 October 2003; accepted 25 October 2003

ABSTRACT

Mixed malaria infections, *Plasmodium falciparum* and *P. vivax*, are suspected to occur at a greater frequency than is detected by conventional light microscopy. In order to determine the year round pattern of transmission and the frequency of mixed infections in malaria endemic area, we carried out a prospective comparison of diagnosis by conventional light microscopy and nested PCR in Chahbahar district, south-eastern part of Iran. Out of 280 Giemsa-stained slides, 158 (56.42%) were identified as having only *P. vivax* and 89 (31.78%) were *P. falciparum* infection by microscopy. Only eight slides (2.8%) were interpreted as having mixed *P. vivax-P. falciparum* infections and 25 (8.9%) were negative. Comparing to the microscopy results, the PCR detected 33 more mixed infections. These results showed that the number, of mixed infections was increased during April to September and reduced after September, although malaria cases with only *P. falciparum* were increased. The possibility that malaria patients in Chahbahar district may have undetected mixed infections during first peak of transmission should be kept in mind because of the specific therapy required both for *P. falciparum* and for radical cure of *P. vivax*. *Iran. Biomed. J.* 8 (2): 89-93, 2004

Keywords: Malaria, *P. falciparum*, *P. vivax*, Mixed infections, PCR

INTRODUCTION

One of the most important problems in controlling the morbidity and mortality caused by malaria is limited access to effective diagnosis and treatment in areas where malaria is endemic [1]. Clinical diagnosis of malaria still depends on the visualization of parasites by light microscopy of Giemsa-stained thick and thin blood smears. This procedure is cheap and simple, but it is labor intensive and requires personnel who are well trained in the morphological differentiation of the *Plasmodium* species [2] for successful diagnosis, which leads to the proper treatment. When very low parasitemia is encountered, a situation frequently found with immune populations or when drugs are taken at sub-curative levels, microscopic examination of the blood smear is required 15 min or more for detection of the

parasites [3]. Recently, for the detection of *Plasmodium* species, rapid non-microscopic tests such as PCR, have been introduced to overcome problems associated with time constraint and low sensitivity in diagnosing malaria infections with a low level of parasitemia by microscopy [4-8].

Malaria is one of the major public health problems in southeastern part of Iran. Annual Parasite Incidence (API) was reported to be 8.74 per 1,000 populations [9]. Inherent problems in this part of the country are the drug resistance of *P. falciparum* [10, 11] and the vector resistance to insecticides [12], complicated by an increasing rate of imported malaria (mostly *P. falciparum*) from Afghanistan and to a lesser extent from Pakistan.

The purpose of this study was to evaluate the suspected pattern of malaria parasites transmission to determine the frequency of undiagnosed, mixed malaria infections for improving the diagnosis and

*Corresponding author; E-mail: azad@institute.pasteur.ac.ir or zakeris@yahoo.com

control of malaria in this particular malaria endemic area. This has been achieved by assessment of the accuracy of basic microscopy and to compare PCR-based diagnosis with microscopy results, in one-year study in Chahbahar district of Sistan and Baluchistan province in southeastern part of Iran.

MATERIALS AND METHODS

Population and study area. The location and characterization of the Chahbahar district have been described previously [13]. Briefly, Chahbahar belongs to Sistan and Baluchistan province in southeastern part of Iran. Malaria transmission occurs through the year with two peaks in May-June and October-November. *P. vivax* is dominant during first peak; but *P. falciparum* is responsible for about 45% of the cases in second peak. A total of 280 consent suspected patients aged from 2 to over 50 years attended at the Malaria Clinic (Public Health Department, Sistan and Baluchistan province, Chahbahar, Iran) were invited to participate in this study during April 2001 to March 2002. Venous blood (2 ml) was obtained from patients with slide-confirmed Plasmodium infection by the clinic staff before treatment. Samples were stored at -20°C.

Malaria parasite detection:

Microscopy. Thick and thin blood smears were made from finger-prick samples, stained with 10% Giemsa and examined under oil-immersion (100 ×) by expert microscopists at the Chahbahar Malaria Clinic. All the smears with collected blood samples were sent to the Malaria Laboratory (Biotechnology Department of the Pasteur Institute of Iran, Tehran). To confirm the results, the slides re-examined for 100 fields. The percentage of the parasitemia was calculated in the main laboratory as described previously [13].

DNA preparation. Extraction of parasite DNA was carried out as described by Snounou *et al.* [3]. Briefly, the erythrocytes were lysed and treated with saponin followed by proteinase K. The parasite DNA was extracted using a phenol: chloroform mixture and the pelleted DNA were resuspended in TE buffer (10 mM Tris-HCL pH 8.0). The DNA used as positive controls for amplification reactions were as follow: *P. vivax* infected blood collected previously from an infected patient, *P. falciparum* infected blood was obtained from *in vitro* cultured parasites routinely maintained at the Malaria Research Group. *P. malariae* DNA was provided

kindly by G. Snounou (Unite de Parasitologie Biomedicale, the Pasteur Institute, France).

Detection of parasites by PCR. *P. vivax*, *P. falciparum*, and *P. malariae* DNA were detected by nested PCR amplification of the small sub-unit ribosomal ribonucleic acid (ssrRNA) genes using the primers and cycling parameters described by Snounou *et al.* [14]. Two negative controls were included in each set of amplification reactions. First control was with no DNA and the second one was from genomic DNA prepared from healthy individuals with no history of malaria, living in non-malarious areas of the country.

The amplified products were resolved by 2%-2.5% agarose gel electrophoresis and stained with ethidium bromide for visual detection by ultraviolet transillumination.

RESULTS

Two hundred and eighty blood samples from suspected malaria patients were collected and examined using thick blood film analysis in Chahbahar district. One hundred and twenty samples were collected during April-September 2001 and also 160 samples from September 2001-March 2002. Two hundred and twenty three of the participated patients (79.6%) were male and 57 were females (20.4%). Fifty-four percent of cases were local inhabitants with Iranian nationality and 46% were from Afghanistan and Pakistan.

By light microscopy, 247 (88.21%) out of 280 Giemsa-stained slides were positive. One hundred and fifty eight slides (56.42%) were identified as having only *P. vivax* and 89 (31.78%) and *P. falciparum* infection. Only eight (2.8%) and 25 (8.9%) slides were interpreted as having mixed *P. vivax-P. falciparum* infections and slide-negative, respectively (Tables 1 and 2). The thin films showed that parasitemia ranged from 0.001% to 6%.

PCR analysis of blood samples. The results of the PCR assays of the blood samples are shown in Tables 1 and 2. Plasmodia were detected in 265 (94.64%) blood samples. One hundred and forty five (51.78%) infections were due to *P. vivax* only and 79 (28.21%) had *P. falciparum* infection alone. Forty-one (14.64%) patients were found to be simultaneously infected with both *P. vivax-P. falciparum* mixed infections and 15 samples were also negative (Tables 1 and 2).

Table 1. Comparison of nested PCR assay with Giemsa staining for detection of plasmodium infection in malaria infected patients during April-September, 2001.

PCR diagnosis	Microscopically diagnosis				
	<i>P. v</i>	<i>P. f</i>	<i>P. v + P. f</i>	Negative	Total
<i>P. v</i> *	61	0	1	8	70 (58.3%)
<i>P. f</i> **	0	12	0	0	12 (10.0%)
<i>P. v + P. f</i>	23	8	2	1	34 (28.4%)
Negative	0	0	0	4	4 (3.30%)
Total	84 (70%)	20 (16.7%)	3 (2.5%)	13 (10.8%)	120

P. v*, *P. vivax*; *P. f*, *P. falciparum*.

Eight out of 25 samples microscopically diagnosed as negative were positive as *P. vivax* only and one negative sample had *P. falciparum* infection by nested-PCR assay. One of the samples, initially misdiagnosed as negative by light microscopy was also diagnosed by PCR as a mixed infection. All 10 microscopically diagnosed negative samples were positive by PCR and confirmed as positive by repeating extraction and the nested PCR assay. With nested-PCR assay, using malaria specific primers, no *P. malariae* were detected in any of the 280 samples tested. A typical gel is shown in Figure 1.

The examination of 120 collected blood samples during April to September 2001 by light microscopy showed that 3 (2.5%) samples had mixed infections and 13 (10.8%) were slide-negative. Comparing to light microscopy, PCR assay showed that out of 120 samples, 34 (28.4%) had mixed infections, diagnosed microscopically as *P. vivax* (19.1%) and *P. falciparum* (6.6%). One of the 3 mixed infections diagnosed microscopically was *P. vivax* only with PCR assay. The PCR also detected *P. vivax* (6.6%) and mixed *P. vivax-P. falciparum* (0.8%) infections in samples from four (3.3%) cases that were microscopically negative (Table 1).

However, out of 160 collected samples during September 2001 to March 2002, five (3.12%) were mixed infections. The 12 (9.37%) negative cases

were analyzed by thick blood film. The PCR assay detected seven (4.37%) mixed infections; three of them diagnosed microscopically as *P. falciparum*. One out of five mixed infections diagnosed by light microscopy was also *P. vivax* infection only. The PCR also detected one *P. falciparum* DNA in samples from 12 subjects who were microscopically negative (Table 2). The number of cases with *P. falciparum* infection was increased from 20 to 69 cases from first to second malaria transmission peaks (Tables 1 and 2).

DISCUSSION

Transmission pattern of malaria parasite is specific in each endemic area and thus it could not be applicable to extend the findings of a study in one area to another areas. It is why having the precise data on transmission pattern will enable us to design a more efficient control program and to apply new tools for its implementation.

Previous studies have shown that microscopy method cannot provide a precise estimation of transmission pattern [3, 4, 13]. However, microscopy in combination with PCR method will generate more reliable data for those who are responsible in control programs. Our previous study in Chahbahar during the first peak of malaria transmission confirmed the efficiency of such

Table 2. Comparison of nested PCR assay with Giemsa staining for detection of plasmodium infection in malaria infected patients during September 2001-March 2002.

PCR diagnosis	Microscopically diagnosis				
	<i>P. v</i>	<i>P. f</i>	<i>P. v + P. f</i>	Negative	Total
<i>P. v</i> *	74	0	1	0	75 (46.87%)
<i>P. f</i> **	0	66	0	1	67 (41.87%)
<i>P. v + P. f</i>	0	3	4	0	7 (4.37%)
Negative	0	0	0	11	11 (6.87%)
Total	74 (46.25%)	69 (43.12%)	5(3.12%)	12(9.37%)	160

P. v*, *P. vivax*; *P. f*, *P. falciparum*.

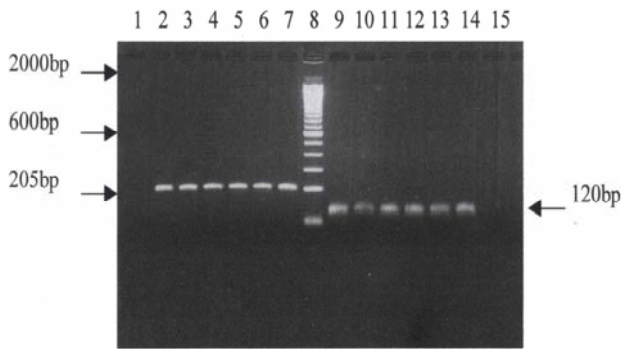


Fig. 1. Agarose gel electrophoresis of nested PCR products from clinical specimens, using species-specific oligonucleotide pairs for both *P. falciparum* (lane 2 to 7) and *P. vivax* (lane 9 to 14) infections. Lane 8 contains 100 bp ladder marker. The negative controls were uninfected human blood (Lane 1 and 15).

comparative studies [13]. The present study aimed to clarify whether the high prevalence of unexpected mixed infections in a low endemic area like Chahbahar, is a characteristic of first peak or it is a normal phenomenon in a year-round transmission cycle. This aim has been achieved by follow-up molecular diagnosis of malaria cases in second peak. The out coming results of this study provided some evidence on pattern of mixed infection, which could be used in designing preventive measures for accurate diagnosis of plasmodium species and treatment of cases.

We showed in our pervious work that the number of malaria cases, the ratio of *P. vivax* to *P. falciparum* and the level of mixed infection were increased from April to September [13]. However, to complete the pattern of transmission in one year, sample collections were continued after September till March. We found that the number of mixed infections reduced after September, although, malaria cases with *P. falciparum* were increased. This may be due to the prevalence and the ability of vector species to simultaneously transmit the different parasite species. Although this needs further clarification, however, the presence of up to seven different anophline species in our study area (Djadid, personal communication) will support the complexity of multiplication and transmission of malaria parasites by different vectors.

In mixed *P. vivax* and *P. falciparum* infections, there is a tendency for one species to dominate the other. In our cases, *P. vivax* parasite was dominant species during the first peak and most *P. falciparum* infection could not be detected microscopically due to very low parasitemia. A satisfactory explanation for this phenomenon is still lacking, but may be due to competition at the level of the host red blood cell

or cross-species immunity [15]. Mixed malarial infections are sometimes overlooked microscopically and may be expected to be diagnosed by the PCR method [3, 4, 13, 16]. Subjects with a negative blood film but a positive PCR result for *P. vivax* and *P. falciparum* probably had very low parasitemia, which could not be detected microscopically. It seems, therefore, that for evaluation of sub-patent parasitemia on the spread of *P. vivax* or *P. falciparum* in study area, more sensitive detection methods such as PCR are needed. The PCR is a valuable method for detecting low-level parasitemia, which can act as a reservoir for the parasite in areas where malaria transmission is unstable. Successful treatment of these cases underpins the long-term success of malaria control programmes.

In conclusions, drug selection for the treatment of malaria depends on species of malaria parasite present. The possibility that malaria patients in Chahbahar district may have undetected mixed infections during first peak of transmission should be kept in mind because of the specific therapy required both for *P. falciparum* and for radical cure of *P. vivax*. In such place, it is essential to reinforce sensitive nested PCR detection of malaria parasites with microscopically diagnosis in order to improve the management of clinical malaria and the detection of potential malaria reservoirs. Correct diagnosis and also treatment of those reservoirs can reduce the number of malaria-infected individuals who carry the parasites between populations and also reduce the risk of re-introducing of malaria into the areas, where an interruption of transmission had been previously achieved. Also, the local clinicians may be worried about undetected of mixed infections in malaria patients for effective treatment and this study suggested that maintenance of a level of suspicion is appropriate. Although the PCR is not practical for the diagnosis of mixed infections in the clinical setting, we suggest that the results presented here can be used to emphasize careful gathering of epidemiological facts and close clinical monitoring of malaria patients in order to provide correct diagnosis and effective treatment.

ACKNOWLEDGEMENTS

We thank the Malaria Division, Center for Diseases Management and Control (CDMC), Iran, for their cooperation. We are grateful for the hospitality and generous collaboration of Zahedan University of Medical Sciences (DR. M.T. Tabatabai), staff in Public Health Department,

Sistan and Baluchistan province, Chahbahar District (Dr. Bayat and Mr. Gorgij) for their assistance in collecting blood samples from the field. We are also grateful to all members in the Department of Biotechnology, Pasteur Institute of Iran, especially Dr. Zeinali.

REFERENCES

1. Roll Back Malaria, Prevention and control of malaria epidemics. WHO/CDS/RBM/2002.
2. Tham, J.M., Lee, S.H., Tan, T.M.C, Ting, R.C.Y. and Ursula, A.K.K. (1999) Detection and species determination of malaria parasites by PCR: comparison with microscopy and with Parassight-F and ICT malaria Pf tests in a clinical environment. *J. Clin. Microbiol.* 37 (5): 1269-1273.
3. Snounou, G., Viriyakosol, S., Jarra, W., Thithong, S. and Brown, K.N. (1993a) Identification of the four human malaria parasite species in field samples by polymerase chain reaction and detection of high prevalence of mixed infections. *Mol. Biochem. Parasitol.* 58: 283-292.
4. Brown, A.E., Kain, K.C., Pipithkul, J. and Webster, H.K. (1992) Demonstration by the polymerase chain reaction of mixed *Plasmodium falciparum* and *P. vivax* infections undetected by conventional microscopy. *Trans. R. Soc. Trop. Med. Hyg.* 86: 609-612.
5. Sethabutr, O., Brown, A., Panyim, S., Kain, K.C., Webster, H.K. and Echeverria, P. (1992) Detection of *Plasmodium falciparum* by polymerase chain reaction in a field study. *J. Infect. Dis.* 166: 145-148.
6. Wataya, Y., Arai, M., Kubochi, F., Mizukoshi, C., Kakutani, T., Ohta, N. and Ishii, A. (1993) DNA diagnosis of falciparum malaria using a double PCR technique: a field trial in the Solomon Islands. *Mol. Biochem. Parasitol.* 58: 165-168.
7. Khoo, A., Furuta, T., Abdullah, N.R., Bah, N.A., Kojima, S. and Wah, M.J. (1996) Nested polymerase chain reaction for detection of *Plasmodium falciparum* infection in Malaysia. *Trans. R. Soc. Trop. Med. Hyg.* 90: 40-41.
8. Singh, B., Cox-Singh, J., Miller, A.O., Abdullah, M.S., Snounou, G. and Rahman, H.A. (1996) Detection of malaria in Malaysia by nested polymerase chain reaction amplification of dried blood spots on filter papers. *Trans. R. Soc. Trop. Med. Hyg.* 90: 519-521.
9. Sadrizadeh, B. (2001) Malaria in the world, in the eastern Mediterranean region and in Iran: Review article. WHO/EMRO Report. pp. 1-13.
10. Edrissian, G.H., Nateghpoor, M., Afshar, A., Sayedzadeh, A., Mohsseni, G.H., Satvat, M.T. and Emadi, A.M. (1999) Monitoring the response of *Plasmodium falciparum* and *P. vivax* to anti-malarial drugs in the malarious areas in southeast Iran. *Arch. Ir. Med.* 2: 61-66.
11. Edrissian, G.H. and Afshar, A. (1985) Preliminary study of the response of *Plasmodium falciparum* to chloroquine in Sistan and Baluchistan province of Iran. *Trans. R. Soc. Trop. Med. Hyg.* 79: 563-564.
12. Manouchehri, A.V., Zaim, M. and Emadi, A.M. (1992) A review of malaria in Iran, 1975-1990. *J. Am. Mosq. Control Assoc.* 8: 381-385.
13. Zakeri, S., Najafabadi, S., Zare, A. and Djadid, D.N. (2002) Detection of malaria parasites by nested PCR in southeastern, Iran: Evidence of highly mixed infections in Chahbahar district. *Malar. J.* 8: 1 (1): 2-6.
14. Snounou, G., Viriyakosol, S., Zhu, X.P., Jarra, W., Pinheiro, L., do Rosario, V.E., Thaithong, S. and Brown, K.N. (1993b) High sensitivity of detection of human malaria parasites by the use of nested polymerase chain reaction. *Mol. Biochem. Parasitol.* 61: 315-320.
15. Maitland, K., Williams, T.N. and Newbold, C.I. (1997) *Plasmodium vivax* and *P. falciparum*: biological interactions and the possibility of cross-species immunity. *Parasitol. Today* 13: 226-231.
16. Oliveria, D.A., Shi, Y.P., Oloo, A.J., Boriga, D.A., Nahlen, B.L., Hawley, W.A., Holloway, B.P. and Lal, A.A. (1996) Field evaluation of a polymerase chain reaction-based non-isotopic liquid hybridization assay for malaria diagnosis. *J. Infect. Dis.* 173 : 1284-1287.