

Short Report

## Detection of Survivin Gene Expression in Formalin-Fixed Paraffin-Embedded Tissues of Human Osteosarcoma: Its Potential Usefulness in Diagnosis and Prognosis of Bone Tumors

Esmail Babaei<sup>1</sup>, Seyed Javad Mowla\*<sup>1</sup>, Shams Shariat Torbaghan<sup>2</sup> and Mojtaba Emadi Baygi<sup>1</sup>

<sup>1</sup>Dept. of Genetics, Faculty of Basic Sciences, Tarbiat Modarres University, Tehran, P.O. Box. 14115-175; <sup>2</sup>Cancer Institute, Imam Khomeini Hospital, Tehran University of Medical Sciences, Tehran, Iran

Received 8 August 2004 ; revised 13 July 2005; accepted 20 November 2005

### ABSTRACT

Osteosarcoma is a relatively uncommon malignancy; however, it is the most common form of primary malignant bone tumors in human. Diagnosis and prognosis of patients with osteosarcoma is limited to clinico-radiopathological parameters, whereas molecular markers of tumor aggression have been poorly identified. Survivin, an inhibitor of apoptosis (IAP), is unique for its expression in human tumors and fetal tissues but not in non-dividing normal adult cells. It mediates suppression of apoptosis in many cancers including bone tumors, and plays a role in tumor progression and chemotherapy resistance. In the present study, the expression of survivin was evaluated by hemi-nested RT-PCR for amplifiable mRNA extracted from 23 formalin-fixed, paraffin-embedded (FFPE) specimens of high-grade osteosarcoma as well as 8 non-tumoral bone tissues.  $\beta$ 2-microglobulin ( $\beta$ 2m) gene expression was also evaluated, and used as an internal control. Survivin gene expression was detected in 82.6% (19/23) of high-grade osteosarcomas. In contrast, there was no gene expression in non-tumoral bone samples as well as the normal tissues obtained from the margin of some osteosarcoma samples. In conclusion, our data revealed that the expression of survivin is limited to osteosarcoma cells and associated with high-grade malignancies. Therefore, evaluating surviving gene expression might have a potential usefulness in diagnosis and prognosis of bone tumors. *Iran. Biomed. J.* 10 (1): 39-45, 2006

**Keywords:** Survivin, Osteosarcoma, Formalin-fixed, Paraffin-embedded (FFPE), Hemi Nested RT-PCR

### INTRODUCTION

Osteosarcoma is a relatively uncommon neoplasm, a fact that precludes determination of its true incidence. Nevertheless, it is the most common form of primary malignant bone tumors in human [1]. Osteosarcoma exhibits a peak in manifestation during the second and third decade of life, with an additional smaller peak after age 50 [1, 2]. The diagnosis, prognosis and treatment of osteosarcoma require a multidisciplinary approach involving family physician, orthopedic oncologist, radiologist and pathologist so that sometimes they have a

diversity of opinions in their decisions [3]. Therefore, the most important problem for managing the treatment procedures of this cancer is the lack of suitable clinico-radiopathological criteria for classifying the tumors appropriately in respect to the nature of malignancy [1, 4, 5].

In recent years, numerous molecular studies of osteosarcoma have been undertaken that have yielded varied and often conflicting results [2, 6]. So far these studies have been of limited value in diagnosis, prognosis and understanding the molecular events driving tumorigenesis in osteosarcoma. Additionally, the overall rarity of these tumors contributes significantly to the

\*Corresponding Author; E-mail: sjmowla@modares.ac.ir

difficulty in their studies at molecular level [1, 7]. Using formalin-fixed, paraffin-embedded (FFPE) tissue sources is a way to obtain enough samples required for determination of the molecular events causing the malignant behavior of osteosarcoma [8].

Tumor growth depends on two main factors: cell proliferation and cell death by apoptosis [9]. Apoptosis is a form of cell death characterized by morphological, biological and genetic features. Abnormalities of apoptosis may lead to uncontrolled cellular proliferation and ultimately carcinogenesis. Several studies have reported significant correlations between apoptosis and prognosis in malignant tumors including lung cancer [10], breast cancer [11] and esophageal cancer [12].

The regulation of apoptosis may play a central role in the development of neoplastic cellular proliferating processes and may exert a strong influence on tumor progression [13]. Survivin, an inhibitor of apoptosis protein (IAP), is expressed both during normal fetal development and in a broad spectrum of human cancers, but is not expressed in most differentiated, non-dividing tissues [14]. Since there is a correlation between expression of survivin and unfavorable outcome of cancer, it may be used as a specific molecular marker for prognosis and classification of malignant tumors [15].

In the present study, we investigated the potential usefulness of survivin gene expression as a tumor marker for diagnosis and prognosis of osteosarcoma. Our data have revealed that the expression of survivin is restricted to high-grade osteosarcoma with no expression in non-tumoral bone tissues as well as normal margins of osteosarcoma specimens. This finding indicates that the evaluation of survivin gene expression might be a useful molecular marker for prognosis and classification of human osteosarcoma.

## MATERIALS AND METHODS

**Sample collections.** FFPE specimens were obtained from the archival collection of Pathologic Department in Cancer Research Institute of Imam Khomeini Hospital of Tehran University of Medical Sciences (Iran). A total of 31 samples from 23 patients with subtype of high-grade osteosarcoma and 8 non-tumoral bone samples including 5 non-tumoral bones and 3 tumor marginal bones were collected. Previous histopathological reports of all

cases re-examined and confirmed by a bone pathologist (Dr. Shams Shariat). Also, we categorized patients' samples in 3 groups: 9 biopsy specimens from patients referring at first time, 8 resected samples that have undergone surgical resection of their tumors after chemotherapy and 6 samples from amputated limbs (having previous resection and chemotherapy) that had expanded *in situ* or with local metastasis in related bone. Personal and pathological features of patients are summarized in Table 1.

**RNA extraction.** RNA was extracted from FFPE tissues by FFPE high pure RNA isolation kit (Ambion Co., Texas, USA) as instructed by manufacturer. Briefly, 3-5 ten-micrometer tissue sections were obtained from each FFPE blocks. Cleaning the microtome blade with xylene and ethanol between each new sectioning prevents carrying over tissues from block to block. Immediately, the obtained sections were processed for RNA extraction. Deparaffinization was carried out by xylene in two steps, for complete elimination of paraffin. After deparaffinization, tissue samples were incubated and digested in proteinase K solution for 5 hours. Then, contaminating DNA eliminated by DNase I (accompanied by RNA isolation kit, Ambion Co., Texas, USA) treatment. The quantity and purity of extracted RNA was determined by UV spectrophotometry and agarose gel electrophoresis. The appearances of rRNA on agarose gel as well as the A260/A280 ratio were both suggested that the quantity and quality of extracted RNA from FFPE samples were much less than the one from fresh tissues.

**Primer design.** The sequences of human  $\beta 2m$  (as an internal control) and survivin were obtained from published sequences in the GeneBank nucleic acid database (access number of NM-004048 and NM-001168, respectively). Specific primers were designed by using genrunner software (version 3.6) and synthesized by MWG Co. (Germany).

We designed primers on different exons or intron-exon boundaries, so that PCR products derived from amplified cDNA would be smaller than those derived from genomic DNA. The sequence and location of the primers are listed below:

Human  $\beta 2m$ :

HBF1: 5'- CTA CTC TCT CTT TCT GGC CTG-3' (94-114),

HBF2: 5'- CTA TCC AGC GTA CTC CAA AG-3' (114-138),

HBR: 5'- GAC AAG TCT GAA TGC TCC AC-3'  
(284-265),  
Human survivin:  
HSF: 5'- ACC ACC GCA TCT CTA CAT TC-3'  
(96-115),

HSR1: 5'- GAA GAA ACA CTG GGC CAA g-3'  
(208-226),  
HSR2: 5'- GTT CCT CTA TGG GGT CGT C-3'  
(260-278).

**Table1.** Personal and pathological features of examined cases. The Table shows three groups of specimens including biopsy (BT1-9), resected (RT1-8), and amputated (AT1-6) samples. The mean age of patients are 17 (9-25) years, except for case BT8 whom was 46. All pathological features were summarized from histopathological reports confirmed by an expert bone oncologist. BT, biopsy samples ; RT, resected samples ; AT, amputated samples.

RT-PCR	Pathological features	Location	Age/Sex	Case No
+	High mitotic index, hypercellular neoplastic tissue conformation, calcification and sarcomatous ossification, invasion to skeletal muscles	Right humerus	9/M	<b>BT1</b>
+	Osteoid formation, prominent nuclei with extraordinary mitosis, abundant giant cells	Right distal femur	16/M	<b>BT2</b>
-	Moderate mitosis, low cellularity, osteoid formation, high necrosis	Left leg	17/M	<b>BT3</b>
+	High N/C, moderate to high mitosis, diverse paternal cellularity and differentiation	Distal femoral bone	22/F	<b>BT4</b>
+	Pleomorphic and Spindle cells, atypical mitosis, regions with osteogenesis	Distal femoral bone	25/M	<b>BT5</b>
-	Undifferentiated cells, patches of necrosis, osteoid formation, low atypical mitosis	Right humerus	22/M	<b>BT6</b>
-	Undifferentiated cells with narrow chromatin and occasionally vesicular, ossification regions, pleomorphism	Right femoral bone	16/F	<b>BT7</b>
+	Necrosis, hypercellular plates, multinuclear giant cells, osteoid formation	Left femoral bone	13/F	<b>BT8</b>
+	Dedifferentiated and atypical neoplasms, hypercellular regions, pleomorphic nuclei	Proximal tibia	19/M	<b>BT9</b>
+	Neoplastic tissue, osteoid formation, patches of necrosis, sometimes with mineralization	Left femoral bone	19/M	<b>RT1</b>
+	High N/C, osteoid, chondroid formation	Right hemi mandibular	24/M	<b>RT2</b>
+	Pleomorphic and spindle cells, hyperchromic regions, necrosis and hemorrhage	Left femoral bone	16/M	<b>RT3</b>
+	Irregular skeletal trabeculae, pleomorphic osteocytes, chondroid formation, spindle cell types	Distal femoral bone	23/M	<b>RT4</b>
+	Neoplastic tissue composed of isolated on connected lobular cartilage, central part of the lobules are differentiated, hypercellular plates	Left leg	16/F	<b>RT5</b>
+	Pleomorphic nuclei including several nucleoli	Left acetabulum	46/M	<b>RT6</b>
+	High patches of necrosis, calcification, giant cells	Distal femoral bone	13/F	<b>RT7</b>
+	Pleomorphic nuclei, multinucleated nuclei, giant tumoral cells, moderate mitosis, massive necrosis	Left distal femur	18/F	<b>RT8</b>
+	Hypercellular plates, moderate pleomorphism, high mitosis	Left leg	25/M	<b>AT1</b>
+	Abundant necrotic patches, high N/C, abundant giant cells, invasion to trabeculae	Left leg	22/F	<b>AT2</b>
-	High N/C, massive necrosis, osteoid formation, sometimes with mineralization	Left leg	11/F	<b>AT3</b>
+	Neoplastic skeletal blades, spindle giant cells, osteoid formation	Left leg	13/F	<b>AT4</b>
+	Localized metastasis, massive necrosis, differentiated and undifferentiated tissue	Knee joint	17/F	<b>AT5</b>
+	High cellularity, 30-35% necrosis	Forequarter amputation	20/F	<b>AT6</b>



**Fig 1.** RT-PCR analysis of survivin expression in biopsy samples (BT1-9). Lane 1 corresponds to the DNA marker. Lower bands (131bp) in all lanes represent survivin, while the upper bands (166 bp) are related to  $\beta$ 2m. In negative control (N.C.) distilled water used instead of cDNA in PCR reaction. Note that, in addition to N.C. three of BT samples were also negative for lower band (survivin).

**Hemi nested RT-PCR reaction.** The same amount of the extracted RNA (24  $\mu$ l) from each sample was used for cDNA synthesis. Reverse transcription was performed by reverse transcriptase enzyme (Fermentase Co., Lithuania) and specific primers for each gene including HBR for  $\beta$ 2m and HSR2 for survivin in one tube (40  $\mu$ l final volume). First round of PCR was performed in a final volume of 50  $\mu$ l and the reaction was followed as described previously [16]. PCR amplification of survivin was performed on Techne thermal cycler using HSR2 (as reverse primer) and HSF (as forward primer). The conditions of the reaction was as follows: initial denaturation at 94°C for 150 s, followed by 35 cycles of denaturation at 94°C for 30 s, annealing at 57°C for 60 s, extension at 72°C for 40 s and a final extension at 72°C for 5 minutes. PCR amplification conditions for  $\beta$ 2m were identical to the one described above except for using specific primers HBR and HBF1. Second round of PCR was performed similar to the one described for the first round of PCR except for using 30 cycles of reactions for both survivin and  $\beta$ 2m as well as using internal forward primers, HBF2 for  $\beta$ 2m and internal reverse primer for survivin.

Finally, 8  $\mu$ l of each PCR products were separated on 1% agarose gel electrophoresis and the expected products were visualized by Et-Br gel staining under Gel Documentation transilluminator (Uvi-tech, England).

## RESULTS

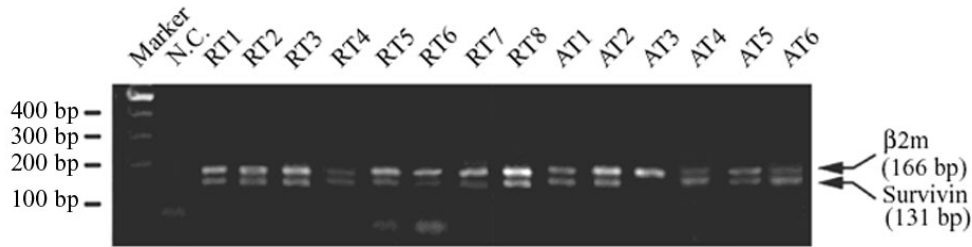
**RNA extraction from FFPE specimens.** All FFPE specimens as well as fresh tissues provided

by Cancer Institute of Imam Khomeini Hospital in Tehran (Iran). The original diagnosis for each patient was re-examined and confirmed by a bone pathologist (Dr. Shams Shariat). The mean age of patients was 17 (9-25) years, except for case number 8 whom was 46 years old. Details of personal and clinico-radiopathological characteristics of all patients were listed in Table 1.

Sections of all FFPE blocks were deparaffinized and total RNA extracted of them. Compare to fresh tissues, the quality and quantity from extracted RNA from FFPE samples was much lower ones (data not shown). A similar finding was obtained by measuring the 260/280 ratios of both samples by UV spectrophotometry (data not shown).

**Detection of survivin expression in FFPE and fresh specimens of osteosarcoma.** Figures 1 and 2 show the results of RT-PCR analysis of survivin gene expression performed on biopsy (BT1-BT9) resected (RT1-RT8) and amputated (AT1-AT6) specimens. Lower bands (131 bp) in all lanes are representing survivin, while the upper bands (166 bp) are an amplified segment of  $\beta$ 2m, which was used as an internal control. RT-PCR results revealed that amplifiable RNA has extracted from all FFPE blocks of osteosarcoma patients. The experiment also detected the expression of survivin in 6/9 (66.6%) of biopsy samples, 8/8 (100%) of resected tumors and 8/9 (88.8) of amputated samples.

While the expression of survivin was detectable in 19/23 (82.6%) of tumor samples, there was no survivin detection in either non-tumoral tissues or non-tumoral margins of tumoral tissues (Fig. 3). As expected,  $\beta$ 2m expression was detectable in all tumoral and non-tumoral samples (Figs. 1-3).



**Fig 2.** RT-PCR analysis of survivin in RT and AT samples. All of the RT and AT cases have undergone at least one chemotherapeutic program. Upper and lower bands correspond to the  $\beta$ 2m and survivin expression, respectively. One sample (AT3) was negative for survivin expression. RT, resected samples; AT, amputated samples; N.C., negative control.

## DISCUSSION

In the present study, we have successfully extracted mRNA from FFPE tissues obtained from archival collection of osteosarcoma patients. The quality and quantity of mRNA were very low, as reported previously by others [8]. Since formalin fixation of the cells results in the fragmentation of mRNA into fragments of approximately 200-250 bases [8], the truncated mRNA was considered in primer designing. The primers were designed in a way to amplify short segments of both  $\beta$ 2m and survivin (166 bp and 131 bp, respectively), allowing amplification of fragmented mRNA.

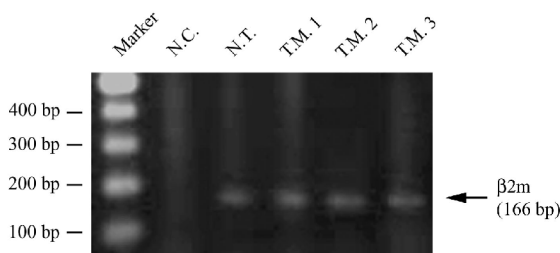
Our results confirm the previous finding of Trieb *et al.* [4], who reported the expression of survivin protein in human osteosarcoma. Our data also extend their immunostaining results at the molecular level by employing RT-PCR technique. Compare to immunostaining, the later technique is more sensitive, allowing the more reliable quantitative and comparative evaluation of survivin gene expression in different grades and stages of

osteosarcoma. Also, since different alternative splice variants of survivin are reported to have different prognostic values [17], evaluating survivin gene expression at RNA level would provide data with higher diagnostic and prognostic value. Determining the extent of the presence of different variants of survivin in osteosarcoma is currently undertaken in our lab.

Re-examining our findings in a case-to-case manner failed to show any significant correlation between the expression of survivin with age, gender and location of tumors. However, the cases, which were negative, showed a high degree of necrosis/apoptosis. The finding may indicate a better prognosis for survivin negative patients; however, this conclusion needs to be further confirmed by following-up the progression of the tumors as well as survival rates of the patients.

Until now, all bone tumors are classified only according to conventional pathologic criteria and the only generally approved prognostic factors for osteosarcoma is tumor size and response to chemotherapy [5, 8]. In recent years, many efforts have been done to introduce a (some) specific molecular marker to clarify the heterogeneous nature of osteogenic sarcoma and predict the potential outcome of the disease. The introduction of an effective molecular marker empowered us to develop new strategies in the treatment of osteosarcoma, e.g., a preoperative stratification of neoadjuvant chemotherapy [3, 5, 18]

The expression of markers indicating a poor prognosis already at biopsy could facilitate a preoperative stratification of neoadjuvant chemotherapy. To date, this stratification is done postoperatively because of the lack of reliable markers [3]. This was the main aim of the current study, where we evaluated the role of survivin as a potential new diagnostic and/or prognostic marker in high-grade osteosarcoma.



**Fig 3.** RT-PCR analysis of survivin expression in non-tumoral samples. The Figure shows the expression pattern of normal samples resected from the margin of related tumors including BT1, BT2 and RT8 and one normal bone as a control. Expression of survivin (131 bp) detected in neither of samples, while all of them shows  $\beta$ 2m expression (166 bp). TM, tumoral margin; N.C.: negative control; BT, biopsy samples; RT, resected samples.

Biopsy patients (66.6%) showed detectable expression of survivin. These are patients that haven't undergone any therapy procedures and referred to institute for first time of their disease. Three biopsy samples were negative for survivin expression, an anticipated finding based on the presence of some patches of apoptosis/necrosis. All of the resected and 5/6 (82.6%) of amputated samples exhibited survivin gene expression. In contrast there was no expression of survivin in non-tumoral tissues as well as the normal bone tissues at the margin of bone tumors. The later findings are in concordance with previous reports indicating a correlation between expression of survivin and an unfavorable outcome in other cancers such as breast cancer [19], colorectal cancer [20], and Hodgkin's lymphoma [21].

In conclusion, the current study demonstrates that the presence of survivin could be an important tumoral marker for diagnosis and the prediction of prognosis of osteosarcoma. Therefore, analysis of survivin expression could facilitate the prediction of a more reliable prognosis, which in turn could lead toward a preoperative stratification and appropriate decisions of the extent of the pre-treatment before surgery.

## ACKNOWLEDGEMENTS

We are grateful to Dr. Mohaghegh and Dr. Nahvijou for their support throughout our research. Also, we thank Hossein Asadi, Mahmood Faraz and Dr. Mahmood Mohammadi for their excellent technical assistance. This work was supported, in part, by a research grant from Cancer Research Center, Imam Khomeini Hospital, Tehran University of Medical Sciences and Health Services (Iran).

## REFERENCES

1. Wolf, M., El-Rifai, W., Tarkkanen, M., Kononen, J., Serra, M., Eriksen, E.F., Elomaa, I., Kallioniemi, A., Kallioniemi, O.P. and Knuutila, S. (2000) Novel findings in gene expression detected in human osteosarcoma by cDNA microarray. *Cancer Genet. Cytogenet.* 123: 128-132.
2. Ragland, B.D., Bell, W.C., Lopez, R.R. and Siegal, G.P. (2002) Cytogenetics and molecular biology of osteosarcoma. *Lab. Invest.* 82 (4): 365-373.
3. Wittig, J.C., Bickels, J., Priebat, D., Jelinek, J., Kellar-Graney, K., Shmookler, B. and Malawer, M.M. (2002) Osteosarcoma: A Multidisciplinary Approach to Diagnosis and Treatment. *Am. Fam. Physician* 65 (6): 1123-1132.
4. Trieb, K., Lehner, R., Stulnig, T., Sulzbacher, I. and Shroyer, K.R. (2003) Survivin expression in human osteosarcoma is a marker for survival. *Eur. J. Surg. Oncol.* 29 (4): 379-382.
5. Bieling, B., Rehan, N. and Winkler, P. (1996) Tumor size and prognosis in aggressively treated osteosarcoma. *J. Clin. Oncol.* 14: 848-858.
6. Trieb, K. and Kotz, R. (2001) Proteins expressed in osteosarcoma and serum levels as prognostic factors. *Int. J. Biochem. Cell Biol.* 33 (1): 11-17.
7. Kufe, D.W., Pollock, R.E., Weichselbaum, R.R., Bast, R.C., Gansler, T.S. and Holland, J.F. (2001) Cancer medicine. BC. Decker Inc., Hamilton, Canada.
8. Krafft, A.E., Duncan, B.W., Bijwaard, K.E., Taubenberger, J.K. and Lichy, J.H. (1997) Optimization of the isolation and amplification of RNA from formalin-fixed, paraffin-embedded tissue: The armed forces institute of pathology experience and literature. Review. *Mol. Diagn.* 2 (3): 217-230.
9. Korsmeyer, S.J. (1992) Bcl-2: a repressor of lymphocyte death. *Immunol. Today* 3: 285-288.
10. MacLuskey, M., Baillie, R., Chandrachud, L.M., Pendleton, N. and Schor, A.M. (2000) High levels of apoptosis are associated with improved survival in non-small cell lung cancer. *Anticancer. Res.* 20: 2123-2128.
11. Gonzalez-Campora, R., Galera, M.R., Vazquez, R.F., Rios, J.J., Fernandez, J.M., Ramos, M.M. and Gomez, A. (2000) Apoptosis in breast carcinoma. *Pathol. Res. Pract.* 196: 167-174.
12. Shibata, H. and Matsubara, O. (2001) Apoptosis as an independent prognostic indicator in squamous cell carcinoma of the esophagus. *Pathol. Int.* 51: 498-503.
13. Igney, F.H. and Krammer, P.H. (2002) Death and anti-death: tumour resistance to apoptosis. *Nat. Rev. Cancer* 2 (4): 277-288.
14. Ambrosini, G., Adida, C. and Altieri, D.C. (1997) A novel anti-apoptosis gene, survivin, expressed in cancer and lymphoma. *Natl. Med.* 3: 917-921.
15. Hanahan, D. and Weinberg, R.A. (2000) The hallmarks of cancer. *Cell* 7: 100 (1): 57-70.
16. Nikpoor, P., Mowla, S.J., Movahedin, M., Ziaee, S.A. and Tiraihi, T. (2004) CatSper gene expression in postnatal development of mouse testis and in subfertile men with deficient sperm motility. *Hum. Reprod.* 19 (1): 124-128.
17. Caldas, H., Jiang, Y., Holloway, M.P., Fangusaro, J., Mahotka, C., Altura, R.A. and Conway, E.M. (2005) Survivin splice variants regulate the balance between proliferation and cell death. *Oncogene* 24 (12): 1994-2007.
18. Slominski, A., Wortsman, J., Carlson, A., Mihm, M., Nickoloff, B. and McClatchey, K. (1999) Molecular pathology of soft tissue and bone tumors. A review. *Arch. Pathol. Lab. Med.* 123 (12): 1246-1259.

19. Van't-Veer, L.J., Dai, H., Van Devijver, M.J., He, Y.D., Hart, A.A., Mao, M., Peterse, H.L., Vander, K.K., Marton, M.J., Witteveen, A.T., Schreiber, G.J., Kerkhoven, R.M., Roberts, C., Linsley, P.S., Bernards, R. and Friend, S.H. (2002) Gene expression profiling predicts clinical outcome of breast cancer. *Nature* 415: 530-536.
20. Vande, W.M., Sancho, E., Verweij, C., Delau, W., Oving, I., Hurlstone, A., Van Der, H.K., Battle, E., Coudreuse, D., Haramis, A.P., Tjon-Pon-Fong, M., Moerer, P., Vanden, B.M., Soete, G., Pals, S., Eilers, M., Medema, R. and Clevers, H. (2002) The  $\beta$ -catenin/TCF-4 complex imposes a crypt progenitor phenotype on colorectal cancer cells. *Cell* 111: 241-250.
21. Kuttler, F., Valnet-Rabier, M.B., Angonin, R., Ferrand, C., Deconinck, E., Mougin, D., Cahn, T. and Fest, T. (2002) Relationship between expression of genes involved in cell cycle control and apoptosis in diffuse large B cell lymphoma: a preferential survivin? cyclin B link. *Leukemia* 16: 726-735.